

## Scientific letter

**Hamstring injury in a rink hockey player. Does sport practice influences in injuries prognosis?**

## ARTICLE INFO

## Keywords:

Hamstring injuries  
Sport injuries  
Rink hockey

## ABSTRACT

We describe the case of a young rink hockey player who sustained a hamstring injury, a transversal rupture of the biceps femoris proximal tendon with retraction of the distal portion while playing. Despite a surgical approach is usually recommended in elite athletes from other sports with this kind of injuries, the biomechanics of the sport must be taken into consideration when the treatment is decided.

**Clinical case**

We present a 21-year-old elite rink-hockey athlete who presented acute pain in the right thigh while falling with hip and knee extended and trunk slightly flexed (the injury mechanism is shown in Supplementary material 1), a stretching mechanism of injury for hamstrings. No previous injuries or preexistent medical conditions or disbalances were reported.

The physical examination showed tenderness in the proximal aspect of back thigh around the ischial tuberosity, accompanied with weakness in the manual muscle tests, with reduction of the strength for hip extension and knee flexion.

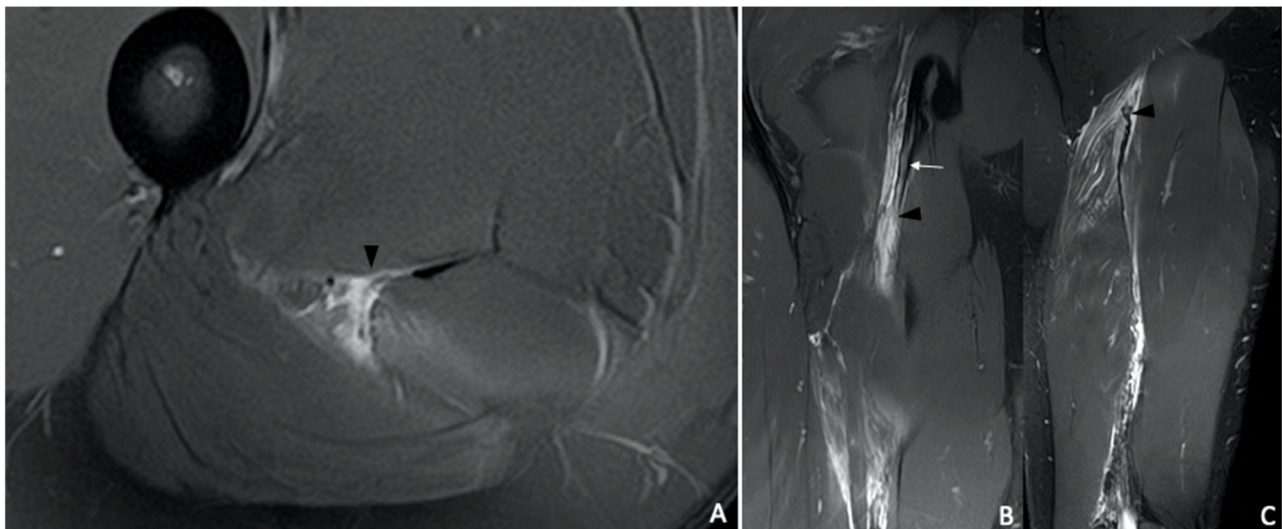
48 h after the injury an MRI was conducted, diagnosing a complete transversal rupture of the free tendon of the *biceps femoris* long head with

retraction of the distal portion (Fig. 1).

Due to the sport characteristics and mechanics of the sports played by the athlete, a conservative management was decided, with rehabilitation treatment. After 6 weeks the athlete started individual skating and after 8 weeks, he started normal practices and games.

**Discussion**

Rink hockey is a contact sport with an injury incidence of 11.2 injuries per 1000 athlete exposures. The lower extremity is the most frequently injured body area, being the muscle tears in the pelvic region the most frequent type of injury. The adductor muscles are the most frequently affected. The hamstring injuries in RH mostly affect goalkeepers, due to their position and the actions they made specially in



**Fig. 1.** MRI Hockey player. Axial (A) and coronal (B and C) proton density fat saturated images. In the axial view there is a complete transversal rupture of the proximal tendon of the long head of biceps femoris (arrowhead), in the coronal view (B) is shown the rupture (arrowhead) with proximal destructuring of the free tendon (thicker and hyperintensity) (arrow). In the more posterior coronal view (C), there is retraction of the distal portion of the rupture (arrowhead) with lost of tendon tension and lost of pennation angle.

<https://doi.org/10.1016/j.apunsm.2024.100465>

Received 15 May 2024; Accepted 27 May 2024

Available online 21 October 2024

2666-5069/© 2024 Published by Elsevier España, S.L.U. on behalf of Consell Català de l'Esport. This is an open access article under the CC BY-NC-ND license (<http://creativecommons.org/licenses/by-nc-nd/4.0/>).

hyperextension of the hamstrings, but in field players are very rare.<sup>1</sup>

Hamstring injuries are common among athletes, particularly in activities requiring explosive burst of extension force or an extreme range of hip flexion or abduction. In sports such as football, rugby, or field hockey these injuries have a great impact in athletes' performance and imply an important burden concerning time-loss injuries.<sup>2</sup> The *biceps femoris* muscle is the most frequently affected, due to the higher solicitation during sprints comparing with both semitendinosus and semimembranosus muscles.<sup>3</sup>

Muscle strains approach is one of the major concerns in sports medicine in the last decade, and its prevention and prognosis have changed in order to establish prevention programs and accurate return-to-play, with the final goal to improve athletes' performance and reduce the injury burden. Concerning hamstring injuries, the surgical approach is being used in complete ruptures of the proximal tendon of the *biceps femoris*, trying to improve the injury outcome in professional athletes.<sup>4</sup> The return-to-play after surgical treatment is 4 to 5 months.<sup>4</sup> The return-to-play of the biceps femoris free tendon injuries who follows a conservative treatment can reach 50 weeks to get to the pre-injury level of performance.<sup>5,6</sup>

Despite the usually proposed surgical approach on injuries located at the free tendon, the specific biomechanics of RH, with less vertical contact, no feet fixation during explosive bursts, and a stride involving forward and lateral (adduction-abduction) movement can arise a conservative approach, as the case we are presenting.

Recent studies showed that an individualized management must be conducted in hamstring injuries.<sup>7</sup> In addition to the characteristics of the athlete, the nature and biomechanics of each sport must be taken in consideration when deciding the better therapeutic options of an injury.

In conclusion, the specific biomechanics of the sports along with the individualized characteristics of the player, his/her position in the field and his/her individual risk factors must be taken in consideration when deciding the injury prognosis.

#### Declaration of competing interest

The Authors declare that they don't have any conflict of interests.

#### Supplementary materials

Supplementary material associated with this article can be found, in the online version, at [doi:10.1016/j.apunsm.2024.100465](https://doi.org/10.1016/j.apunsm.2024.100465).

#### References

1. de Pablo B. *Epidemiologia Lesional De L'hoquei patins*. Thesis. Universitat de Vic-Universitat Central de Catalunya; 2023.
2. Clark BB, Jaffe D, Henn 3rd RF, Lovering RM. Evaluation and imaging of an untreated grade III hamstring tear: a case report. *Clin Orthop Relat Res*. 2011 Nov;469(11):3248–3252.
3. Morin JB, Gimenez P, Edouard P, et al. Sprint acceleration mechanics: the major role of hamstrings in horizontal force production. *Front. Physiol*. 2015;6:404.
4. Jokela A, Stenroos A, Kosola J, Valle X, Lempainen L. A systematic review of surgical intervention in the treatment of hamstring tendon ruptures: current evidence on the impact on patient outcomes. *Ann. Med*. 2022;54(1):978–988.
5. Askling CM, Tengvar M, Saartok T, Thorstensson A. Acute first-time hamstring strains during slow-speed stretching: clinical, magnetic resonance imaging, and recovery characteristics. *Am J Sports Med*. 2007;35(10):1716–1724.
6. Rudisill SS, Kucharik MP, Varady NH, Martin SD. Evidence-based management and factors associated with return to play after acute hamstring injury in athletes: a systematic review. *Orthop J Sports Med*. 2021 Nov 29;9(11), 23259671211053833.
7. Lempainen L, Kosola J, Pruna R, et al. Tears of biceps femoris, semimembranosus, and semitendinosus are not equal-a new individual muscle-tendon concept in athletes. *Scand J Surg*. 2021;110(4):483–491.

Bernat de Pablo<sup>a,b,\*</sup>, Gil Rodas<sup>a</sup>, Martí Casals<sup>b,c</sup>

<sup>a</sup> Futbol Club Barcelona, Barcelona Spain

<sup>b</sup> “Sport, Exercise, and Human Movement” (SEAHM), Universitat de Vic – Universitat Central de Catalunya, Vic Spain

<sup>c</sup> Health and Applied Sciences Department, INEFC Barcelona, Barcelona, Spain

\* Corresponding author.

E-mail address: [bernatdepablo@gmail.com](mailto:bernatdepablo@gmail.com) (B. de Pablo).