

ORIGINAL ARTICLE

Oncologic and functional results of surgical treatment for base of tongue carcinomas

Juan Pablo Díaz Molina,* Juan Pablo Rodrigo, José Luis Llorente, César Álvarez Marcos, Carla Moreno, and Carlos Suárez

Servicio de Otorrinolaringología, Hospital Universitario Central de Asturias, Instituto Universitario de Oncología del Principado de Asturias, Oviedo, Spain

Received March 14, 2010; accepted April 7, 2010

KEYWORDS

Base of tongue carcinoma;
Glossectomy

Abstract

Introduction and objectives: Squamous cell carcinomas at the base of the tongue are usually diagnosed at advanced stages, and their optimal treatment has not been established. The aim of this study was to describe the functional and oncological outcomes of patients with base of tongue carcinomas treated with surgery.

Materials and methods: A retrospective study on 132 patients with base of tongue carcinoma surgically treated in our hospital between 1990 and 2007 was carried out. One patient (0.75%) was in stage I, 8 (6%) were in stage II, 15 (11%) in stage III, 91 (69%) in stage IVA, and 17 (13%) with stage IVB. A total of 92 (70%) patients received postoperative radiotherapy.

Results: Eighty-seven patients (66%) had recurrence: 23 patients (17%) had local recurrence, 15 (11%) regional, 20 (15%) locoregional, 16 (12%) locoregional and distant, and 9 (7%) distant metastases. The disease-specific survival was 34% at 5 years (100% for stages I and II, 44% for stage III, 28% for stage IVA and 12% for IVB; $P=.0004$). Multivariate analysis showed two variables independently associated with worse survival: lymph node metastases classified as N2-3 ($P=.016$) and primary tumours classified as T3-4 ($P=.040$). Adequate oral intake was achieved by 96% of the patients and 79% could be decannulated.

Conclusions: The prognosis of squamous cell carcinomas of the base of the tongue is poor, especially in advanced stages. Surgical treatment provides oncological and functional results similar to other therapeutic modalities.

© 2010 Elsevier España, S.L. All rights reserved.

*Corresponding author.

E-mail address: chescadoc@yahoo.com (J.P. Díaz Molina).

PALABRAS CLAVE

Tumores epidermoides
de base de lengua;
Glosectomía

Resultados oncológicos y funcionales del tratamiento quirúrgico de los carcinomas de base de lengua**Resumen**

Introducción y objetivos: Los carcinomas epidermoides de base de lengua son habitualmente diagnosticados en estadios avanzados, no habiéndose establecido el tratamiento óptimo de los mismos. El objetivo de este estudio es describir los resultados funcionales y oncológicos de los pacientes con carcinomas de base de lengua tratados mediante cirugía.

Material y métodos: Se realizó un estudio retrospectivo en 132 pacientes con carcinomas de base de lengua tratados quirúrgicamente en nuestro Hospital entre 1990-2007. Un paciente (0,75%) se hallaba en estadio I, 8 (6%) en estadio II, 15 (11%) en estadio III, 91 (69%) en estadio IVA, y 17 (13%) en estadio IVB; 92 (70%) de los pacientes recibieron radioterapia postoperatoria.

Resultados: Ochenta y siete pacientes (66%) presentaron algún tipo de recidiva: 23 pacientes (17%) recidiva local, 15 (11%) regional, 20 (15%) loco-regional, 16 (12%) loco-regional y a distancia, y 9 (7%) metástasis a distancia. La supervivencia específica para la enfermedad fue del 34% a los 5 años (del 100% para los estadios I y II, del 44% para el estadio III, del 28% para el estadio IVA y del 12% para el IVB; $p = 0,0004$). El análisis multivariante mostró 2 variables asociadas de forma independiente con una peor supervivencia: las metástasis linfáticas clasificadas como N2-3 ($p = 0,016$) y los tumores primarios clasificados como T3-4 ($p = 0,040$). El 96% de los pacientes consiguieron alimentación oral, y el 79% pudieron ser decanulados.

Conclusiones: El pronóstico de los carcinomas epidermoides de base de lengua en estadios avanzados es pobre. El tratamiento quirúrgico obtiene unos resultados funcionales y oncológicos similares a los de otras modalidades terapéuticas.

© 2010 Elsevier España, S.L. Todos los derechos reservados.

Introduction

Oropharyngeal cancers make up 10%-15% of neoplasms of the head and neck region.¹ Of these, squamous cell carcinomas that are at the base of the tongue (pharyngeal) represent between 20%-35%, and are the second in frequency after lateral wall tumors.² These tumours represent a challenge for head and neck surgeons because they are in an anatomical region difficult to explore, whose large surface allows the invading tumour to grow significantly in depth before producing alarm symptoms. Many of these tumours are submucosal, which makes their early detection even more difficult; many patients consequently arrive at the moment of diagnosis with lymphatic metastases or in locally advanced stages.³⁻⁵

The best option in the treatment of these lesions has still not been established. In early stages (I-II), similar oncological outcomes have been published after treatment with surgery or radiotherapy, with adequate anatomical and functional preservation of the airway and oral feeding.^{1,5,7-10}

However, the treatment of patients with advanced tumours is controversial. There are 3 accepted therapeutic modalities, surgical treatment (with possible additional radiotherapy), chemoradiation or radiotherapy alone. Treated patients, suffering from locally advanced stages, may require partial or total removal of the larynx,¹¹ with a significant decrease in their quality of life. Some authors do not therefore recommend surgical treatment in patients with tumours classified as T3 and T4.^{12,13}

With regard to the treatment of lymph node metastasis, most authors agree on carrying out bilateral lymph node dissections. This is true even with patients in stages I and II, due to the high probability of hidden cervical metastases.^{14,15}

In this study, we present our experience in surgical treatment of patients with pharyngeal squamous cell carcinomas, presenting the functional and oncological outcomes of our patients and comparing them with those published by other authors.

Material and methods

We carried out a retrospective review of patients diagnosed and treated at our hospital for base of tongue squamous cell carcinoma from January 1990 to May 2007. Patients operated for local recurrence, persistence of patients treated with primary radiotherapy and patients with a monitoring period under 24 months were excluded from the study. There were 132 patients who met the inclusion criteria. None of the patients presented distant metastases at the time of surgery. Patients were staged following the TNM classification of the International Union against Cancer (6th edition) for oropharyngeal carcinoma. Patient clinical-pathological data are presented in Table 1.

Of these patients, 5 were female and 127 male. The mean patient age was 58 years (range 38-85). The total number of habitual drinkers was 128 (97%); of these, 7% reported an

Table 1 Characteristics of patients and their tumours

| Characteristic | Number of patients, % |
|--------------------|-----------------------|
| pT classification | |
| T1 | 9 (7) |
| T2 | 27 (21) |
| T3 | 40 (30) |
| T4 | 56 (42) |
| pN classification | |
| N0 | 19 (14) |
| N1 | 18 (14) |
| N2a | 7 (5) |
| N2b | 29 (22) |
| N2c | 37 (28) |
| N3 | 22 (17) |
| Tumoral stage | |
| I | 1 (1) |
| II | 8 (6) |
| III | 15 (11) |
| IVA | 91 (69) |
| IVB | 17 (13) |
| Histological grade | |
| G1 | 57 (43) |
| G2 | 50 (38) |
| G3 | 25 (18) |
| Residual disease | |
| R0 | 110 (83) |
| R1 | 22 (17) |

alcohol intake of less than 50g alcohol/day, 24% consumed alcohol in the range of 50-100 g/day and 65% drank more than 100 g alcohol/day. The total number of smokers was 126 (95%), 60 of whom (49%) consumed fewer than 40 packs/year, 51 patients (40%) smoked between 40-80 packs/year, and 15 patients (11%) over 80 packs/year.

All patients were carefully evaluated before surgery. The decision to opt for surgical treatment was partly based on preoperative imaging studies (CT), but mainly on a clinical evaluation marking the extent of the tumour. Patients with primary tumours in early stages and complete injury exposure were treated by intraoral resections (monopolar resection or microsurgery with CO₂ Laser); the remaining patients were treated with transpharyngeal or transmandibular approaches. A total of 10 patients (8%) underwent intraoral resection, a transmandibular approach was used on 21 (16%) and a transpharyngeal approach on 101 (76%). A total of 48 patients (36%) underwent supraglottic laryngectomy (glosso-epiglottectomy) and 17 patients (13%) underwent a total laryngectomy. A total of 11 patients (8%) underwent total glossectomy with reconstruction using a pedicled pectoralis major flap.

A total of 129 patients (98%) underwent lymph node removal. Of these, 22 patients (17%) underwent unilateral

lymphadenectomy (14 of these were functional dissections and 8 were radical). The other 107 patients (81%) were treated with bilateral lymph node removal (68 with bilateral functional lymph node dissection, 5 with bilateral radical and 34 with functional dissection plus a radical lymph node dissection). In 3 patients, the neck received no treatment whatsoever. The indications for functional lymph node dissection were an absence of palpable adenopathies or the intraoperative finding of lymph nodes without extracapsular extension. Unilateral dissections were usually performed on patients with small unilateral tumours, without midline involvement and with no clinical evidence of bilateral lymphadenopathy. In the remaining patients, the dissections were performed bilaterally.

Ninety-two patients (70%) received postoperative radiotherapy. As a general rule, most patients with lymph node metastasis received adjuvant radiotherapy, especially those with more than 2 positive adenopathies, those who had adenopathies with extracapsular invasion and the N0 patients in locally advanced stages (T4) or with residual disease.

Statistical analysis was carried out using the Chi-square test, with Yates correction when necessary, and Fisher's exact test. Survival was calculated using the Kaplan-Meier method. The log rank method was used to analyse the differences between survival times. Multivariate analysis (Cox regression) was used to determine the impact on survival of the variables that had proved to be statistically significant ($P < .05$) in univariate analysis.

Results

Of the 132 patients studied, 87 (66%) presented recurrences: 23 patients (17%) suffered isolated local recurrence, 15 (11%) cervical recurrence, 20 (15%) loco-regional recurrence, 16 (12%) loco-regional and distant recurrence, and 9 (7%) distant metastases. The average time to onset of recurrence was 13 months (range, 3-47 months). Twelve patients (9%) presented second primary tumours. The incidence of local recurrence was significantly higher ($P = .04$) in tumours classified as T2-T4, compared to T1 (Table 2). Similarly, cervical recurrences were more frequent as the No. classification increased (Table 3), the differences being statistically significant ($P = .007$).

In patients with lymph node metastases, the mean positive nodes upon dissection was 4 (range 1-21). Patients presenting regional recurrence had a mean number of

Table 2 Local recurrence according to the pT classification

| pT classification (n) | Number of patients with local relapses (%) |
|-----------------------|--|
| T1 (9) | 0 |
| T2 (27) | 14 (52) |
| T3 (40) | 20 (50) |
| T4 (56) | 25 (45) |

Table 3 Cervical recurrences according to the No. classification

| pN classification (n) | Number of patients with cervical relapses (%) |
|-----------------------|---|
| N0 (19) | 4 (21) |
| N1 (18) | 3 (17) |
| N2a (7) | 2 (28) |
| N2b (29) | 17 (59) |
| N2c (37) | 12 (32) |
| N3 (22) | 13 (59) |

affected nodes significantly higher than for those who did not present it (4.5 vs 2.8; $P=.015$). Fifty-nine patients (45%) suffered extracapsular invasion; the incidence of regional recurrence in these patients (39%) was not significantly higher than in patients without extracapsular invasion (38%) ($P=.9$). In considering whether the number of dissections influenced the posterior development of regional recurrence, we found that 11 (50%) of the 22 patients who underwent unilateral dissection had regional recurrence, most of them on the untreated side of the neck, while 33 of the 107 patients (30.84%) whose neck was treated bilaterally suffered regional recurrence ($P=.191$). This suggests that the number of dissections performed in patients with pharyngeal tumours affects treatment failure at the regional level. In 1 of the 3 patients (33%) in whom dissection was not carried out, there was cervical lymph node metastasis; this underscores the importance of neck surgery in these patients. Moreover, a statistically significant relationship between the No. classification and the development of distant metastases was found; the latter occurred in 14% of N0-1 patients and in 31% of N2-N3 cases ($P=.045$).

Pathological examination showed that the margins were affected at the microscopic level in 22 patients (15%). Patients with affected margins had a higher incidence of local recurrence (54% vs 43% in patients with clear margins), although these differences were not significant ($P=.16$). This can be attributed to the effect of the postoperative radiation therapy administered to all patients with positive margins.

Disease specific survival at 5 years for the 132 patients was 34% and overall survival 21%. The disease specific survival at 5 years according to tumour stage was: 100%, 100%, 44%, 28%, and 12% for stages I to IVB, respectively ($P=.0004$; Figure 1a). Disease specific survival at 5 years according to the classification of the primary tumour (pT) was: 48%, 46%, 26%, and 25% for T1-T4 patients, respectively ($P=.1$; Figure 1b). Disease specific survival at 5 years based on the pathological lymph node (pN) classification was: 66%, 38%, 28%, and 18% for patients classified as N0, N1, N2, and N3, respectively ($P=.005$; Figure 1c). The histological grade of the tumour did not influence the disease specific survival of these patients ($P=.14$). Administration of postoperative radiotherapy to patients in stage IV significantly increased their disease specific survival. This was 27% in patients who

received radiotherapy, compared with 10% for those not irradiated ($P=.018$; Figure 1d).

In the multivariate analysis, 2 variables resulted statistically significant, independent predictors of worse survival: cervical metastases classified as pN2-3 (RR: 2.19; 95% CI: 1.22-3.93; $P=.008$) and tumours classified as pT3-4 (RR 1.2; 95% CI: 1.01-1.47; $P=.040$).

Patient hospital stay was a mean of 30 days (range 1-120). Post-surgery complications were presented by 76 patients (58%). The most frequent complication was surgical wound infection, which occurred in 33 patients (25%), 27 patients (20%) suffered pneumonia and 11 patients (8%) suffered postoperative bleeding. Three patients (2%) died as a result of these complications. As indicated, 17 patients (13%) required total laryngectomy. In addition, 11 of the 109 patients (10%) who underwent tracheotomy could not be decannulated. Oral feeding was successful in 127 of the 132 patients (96%), while the remaining 5 required permanent gastrostomy for feeding.

Discussion

Oropharyngeal carcinomas are usually diagnosed in advanced stages, especially those of the tongue base. The asymptomatic progression of these lesions, the difficulty in exploring this area and the rich lymphatic drainage of the region are some of the reasons why most of these tumours are diagnosed at stage IV in more than 70% of cases.^{16,17} Our patients presented an even higher proportion of advanced stages: 73% were classified as pT3-T4 and 74% as pN2-N3 (and 45% of them presented extracapsular invasion), so that 82% were in stage IV.

It is very important to choose the most appropriate therapeutic treatment mode, which must also be supported on the basis of the individual characteristics of each patient, the experience of the medical team and the support available at the time of rehabilitating such patients. Most cases require several treatment modes to be combined, as the percentage of patients diagnosed in advanced stages is high.

Oncological outcomes of surgical treatment in early stages can be considered good (100% in our series, although the number of cases in these stages was small), comparable to patients treated with radiotherapy.^{12,18} However, the oncological results in patients with pharyngeal carcinoma in advanced stages are less published in the medical literature. Zhen et al,¹⁷ working with data obtained from the U.S. National Cancer Database, reported that patients with squamous cell carcinoma of the base of the tongue in advanced stages had a better outcome when the therapeutic mode used was surgery with postoperative radiation therapy. In the present study, the low disease specific survival and overall survival at 5 years, combined with the high recurrence rates, confirmed that pharyngeal squamous cell carcinomas are aggressive and have a poor prognosis. These results are similar to those of patients treated with other therapeutic modes. In the review by Zhen et al,¹⁷ the disease specific survival at 5 years in 851 patients with advanced pharyngeal tumours (stages III-IV) treated with radiotherapy was 24.3%, and 25.6% for 651 patients treated with chemoradiotherapy. Disease specific

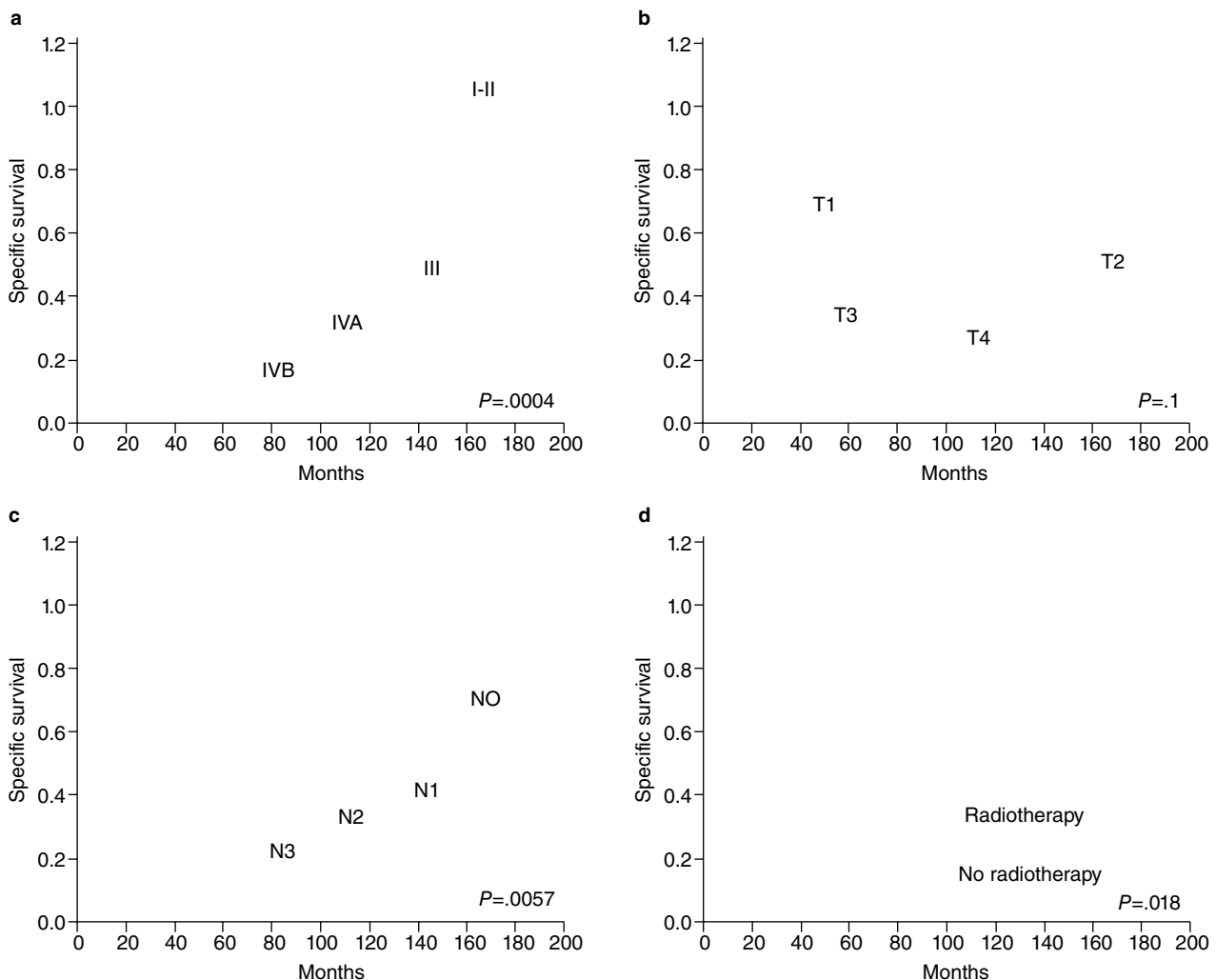


Figure Specific disease rates according to the Kaplan-Meier method, depending on the stage (a), T classification (b), N classification (c) and postoperative administration of radiotherapy in patients with stage IV (d).

survival at 5 years in our patients was similar, given that it was 30% for patients in stages III-IV (44% in stage III and 25% in stage IV).

In our patients, disease specific survival at 5 years was 34%, comparable to other series in which the treatment mode was surgery, showing survival rates between 42%-51%.¹⁷ It should be noted that, in our series, the percentage of patients in advanced stages was 93% (stages III-IV), higher than that in series described by other authors. We must emphasise the importance of aggressive treatment with postoperative administration of radiation therapy in all patients in stage IV (or chemoradiotherapy in patients with high risk factors for recurrence). In our series, survival was significantly lower in some stage IV patients who received no additional treatment.

The main risk factors for the development of oropharyngeal neoplasms are tobacco and alcohol,⁶ present in a large proportion of our patients (95% and 97%). Recently, a lot of emphasis has been given to the aetiological role of human papilloma virus (HPV), especially HPV-16, in the

development of oropharyngeal squamous cell carcinoma. In addition, patients in whom the presence of HPV is detected have a better prognosis, which is markedly better if patients are not smokers. The better prognosis of these tumours can be explained by the fact that HPV-positive patients present a different oncogenic pathway.¹⁹⁻²¹ Although HPV was not studied in our patients, the high proportion of smokers and drinkers leads us to believe that HPV is not important in our series and may partially explain the aggressive behaviour of tumours in our patients.

Neck treatment is a very important factor in the treatment of patients with oropharyngeal tumours. This is even more so given that, in some publications, patient survival depends more on lymph node metastases than on primary tumours.^{22,23} Logically, the presence of lymph node metastases classified as pN2-N3 was also the most important prognostic factor in our series. Most authors recommended carrying out bilateral lymph node dissections. However, in selected cases (T1-T2 N0 with no invasion of the midline), it is possible to perform only a functional lymph node

dissection without compromising survival, although the percentage of lymph node recurrences in the contralateral side of the dissection is higher, as demonstrated in this study.

In most patients, the presence of recurrence indicates a very poor prognosis regardless of whether the recurrence is local, regional or distant. As in other works,^{24,25} we found that the factor that best predicts the development of distant metastases is the No. classification, since these were present in 31% of patients classified as pN2-N3.

The ideal treatment for these patients should ensure high cure rates, in addition to preserving laryngeal function and oral feeding. In our series, the larynx was preserved in 87% of patients, 79% of them could decannulated, and oral feeding was possible in 96% of patients. One possible explanation for the low rate of laryngeal function preservation in comparison with other authors²⁶ is, once again, the high percentage of patients in advanced stages. A significant proportion of these (49%) presented extension to the larynx, which led to the resection being extended to include this organ. Unlike our series, many other series of pharyngeal tumours do not include cases with involvement of the larynx. With respect to swallowing, our results are comparable to those reported by other authors, including those obtained in series including only cases treated by intraoral resection.^{8,16}

In conclusion, in this study we have evaluated the effectiveness and safety of surgical treatment in the management of patients with advanced-stage pharyngeal squamous cell carcinoma. Surgical treatment allows the swallowing function to be maintained in most patients, as well as having good rates of voice preservation. Oncological results are modest but similar to other therapeutic modalities such as radiation and chemoradiation, and we believe that it can be recommended within the therapeutic modalities of choice for the treatment of such patients. It is advisable to subject all patients in stage IV to postoperative radiotherapy because this has shown statistically significant improvement of disease specific survival.

Conflict of interest

The authors declare no conflict of interests.

References

- Moncrieff M, Sandilla J, Clark J, Clifford A, Shannnon K, Gao K, et al. Outcome of primary surgical treatment of T1 and T2 carcinomas of the oropharynx. *Laryngoscope*. 2009;119:307-11.
- Yoshimoto S, Kawabata K, Mitani H, Yonekawa H, Beppu T, Fukushima H, et al. Treatment results for 84 patients with base of tongue cancer. *Acts Otolaryngol Suppl*. 2007;559:123-8.
- Jones A, Rafferty M, Fenton J, Jones T, Husband D. Treatment of squamous cell carcinoma of the tongue base: irradiation, surgery or palliation? *Ann Otol Rhinol Laryngol*. 2007;116:92-9.
- Pitcher M, Martin C. Delay in referral of oropharyngeal squamous cell carcinoma to secondary care correlates with a more advanced stage at presentation, and is associated with poorer survival. *Br J Cancer*. 2006;94:955-8.
- Jones AS, England J, Hamilton J, Heliwell TR. Mandibular invasion in patients with oral and oropharyngeal squamous carcinoma. *Clin Otolaryngol*. 1997;22:239-45.
- Haigentz M, Silver C, Corry J, Genden E, Takes R, Rinaldo A, et al. Current trends in initial management of oropharyngeal cancer: the declining use of open surgery. *Eur Arch Otorhinolaryngol*. 2009;266:1845-55.
- Cosmidis A, Rane JP, Dassonville O, Temam S, Massip F, Poissonnet G. T1-T2 N0 oropharyngeal cancers treated with surgery alone. A GETTEC study. *Eur Arch Otorhinolaryngol*. 2004;261:276-81.
- Grant DG, Salassa JR, Hinni ML, Pearson BW, Perry WC. Carcinomas of the tongue base treated by transoral laser microsurgery, part one: untreated tumors, a prospective analysis of oncologic and functional outcomes. *Laryngoscope*. 2006;116:2150-5.
- Chao KS, Ozyigit G, Blanco AI, Thorstad WL, Deasy JO, Haughey B. Intensity-modulated radiation therapy for oropharyngeal carcinoma: impact of tumor volume. *Int J Radiat Oncol Biol Phys*. 2004;59:43-50.
- De Arruda FF, Puri DR, Zhong J, Narayana A, Wolden S, Hunt M, et al. Intensity-modulated radiation therapy for the treatment of oropharyngeal carcinoma: the Memorial Sloan-Kettering Cancer center experience. *Int J Radiat Oncol Biol Phys*. 2006;64:363-73.
- Suarez C, Rodrigo JP, Herna J, Rosal C, Alvarez JC. Extended supraglottic laryngectomy for primary base of tongue carcinomas. *Clin Otolaryngol*. 1996;121:37-41.
- Hinerman RW, Parson JT, Mendenhall WN, Stringer SP, Cassisi NJ, Million RR. External beam irradiation alone or combined with neck dissection for base of tongue carcinomas: an alternative to primary surgery. *Laryngoscope*. 1994;104:1466-70.
- Dalby ME, Le QT, Maxim PG, Loo BW, Kaplan MJ. Intensity-modulated radiotherapy in the treatment of oropharyngeal cancer: clinical outcomes and patterns of failure. *Int J Radiat Oncol Biol Phys* [Epub ahead of print].
- Reddy AN, Eisele DW, Forastiere AA, Lee DJ, Westra WH, Califano JA. Neck dissection followed by radiotherapy or chemoradiotherapy for small primary oropharynx carcinoma with cervical metastasis. *Laryngoscope*. 2005;115:1196-200.
- Lavertu P, Adelstein DJ, Saxton JP, Secic M, Wanamaker JR, Eliachar I, et al. Management of the neck in randomized trial comparing concurrent chemotherapy and radiotherapy with radiotherapy alone in resectable stage II and IV squamous cell head and neck cancer. *Head Neck*. 1997;19:559-66.
- Camp AA, Fundakowsky C, Petruzzelli G, Emami B. Functional and oncological results following transoral laser microsurgical excision of base of tongue carcinoma. *Otolaryngol Head Neck Surg*. 2009;141:66-9.
- Zhen W, Karnell L, Hoffman H, Funk G, Buatti J, Menk H. The national cancer data base report on squamous cell carcinoma of the base of tongue. *Head Neck*. 2004;26:660-74.
- Foot RL, Olsen KD, Davis DL, Buskirk SJ, Stanley RJ, Kunselman SJ, et al. Base of tongue carcinoma: patterns of failure and predictor of recurrence after surgery alone. *Head Neck*. 1993;15:300-7.
- Chaturvedi AK, Engels EA, Anderson WF, Gillison ML. Incidence trends for human papillomavirus-related and -unrelated oral squamous cell carcinomas in the United States. *J Clin Oncol*. 2008;26:612-9.
- Ritchie JM, Smith EM, Summersgill KF, Hoffman HT, Wang D, Klussman JP. Human papillomavirus infection as a prognostic factor in the carcinoma of the oral cavity and oropharynx. *Int J Cancer*. 2003;104:336-44.
- Hafkamp HC, Manni JJJ, Haesevoets A, Voogd AC, Schepers M, Bot FJ. Marked differences in survival rate between smokers and nonsmokers with HPV 16-associated tonsillar carcinoma. *Int J Cancer*. 2008;122:2656-64.

22. Sessions D, Lenox J, Spector G, Chao C, Chaudry O. Analysis of treatment result for base tongue cancer. *Laryngoscope*. 2003; 113:1252-62.
23. Gourin C, Johnson J. Surgical treatment of squamous cell carcinoma of the base tongue. *Head Neck*. 2001;23:653-60.
24. Vikram V, Strong E, Shah JP, Spiro R. Failure at distant sites following multimodality treatment for advanced head and neck cancer. *Head Neck*. 1984;6:730-3.
25. Alvi A, Johnson J. Development of distant metastasis after treatment of advanced-stage head and neck cancer. *Head Neck*. 1997;19:500-5.
26. Cano E, Lai S, Caylakli F, Johnson J, Ferris R, Carrau R, et al. Management of squamous cell carcinoma of the base of tongue with chemoradiation and brachytherapy. *Head Neck*. 2009; 31:1431-8.