

ORIGINAL ARTICLE

Transphenoidal endoscopic approaches for pituitary adenomas: a critical review of our experience

Miguel Armengot,^{a,*} José María Gallego,^b María José Gómez,^c Juan Antonio Barcia,^d Jorge Basterra,^e Carlos Barcia^b

^aSección de Rinología, Servicio de Otorrinolaringología, Hospital General Universitario, Universitat de València, Valencia, Spain

^bServicio de Neurocirugía, Hospital General Universitario, Universitat de València, Valencia, Spain

^cServicio de Otorrinolaringología, Hospital General Universitario, Valencia, Spain

^dServicio de Neurocirugía, Hospital Clínico, Madrid, Spain

^eServicio de Otorrinolaringología, Hospital General Universitario, Universitat de València, Valencia, Spain

Received April 29, 2010; accepted September 3, 2010

KEYWORDS

Skull base;
Tumour;
Nasal fossae;
Hypopituitarism;
Diabetes insipidus;
Navigator

Abstract

Background: The surgical approach to the pituitary fossae has evolved from transcranial to sublabial and transseptal microscopic ones, up to the current transsphenoidal endoscopic approach.

Objectives: To present our experience in the transnasal transsphenoidal approach for pituitary adenomas and the modifications introduced to improve tumoral resection and to lower iatrogenia.

Material and methods: Over nine years, we operated on 37 patients with pituitary adenomas using the transsphenoidal endoscopic approach. We utilised optical lens of 0° (approach) and 30° (adenoma resection), optic navigator, surgical instruments for nasal endoscopic and pituitary surgery. During the neurosurgical step, the endoscope was fixed by an articulated arm. We acceded to the pituitary fossae by a bilateral sphenoidotomy.

Results: Sphenoid pneumatization was sufficient in all the patients. The more common postoperative complications were diabetes insipidus and endocrinology deficiencies. Postoperative rhinoliquorrhea affected only one patient. No alterations of nasal fossae were observed. Mean patient hospitalisation was five days.

Conclusions: Transsphenoidal endoscopic approach guided by navigator gives significant advantages: Shorter operating time and fewer complications, greater safety and preservation of the nasal passages. Resecting the sphenoidal rostrum and a fragment of adjacent nasal septum improves surgical instrument management into the pituitary fossae and therefore adenoma resection. Endoscope fixation stabilises the vision and allows the second surgeon to help more effectively.

© 2010 Elsevier España, S.L. All rights reserved.

*Corresponding author.

E-mail address: miguel.armengot@gmail.com (M. Armengot).

PALABRAS CLAVE

Base de cráneo;
Tumor;
Fosas nasales;
Hipopituitarismo;
Diabetes insípida;
Navegador

Abordajes transesfenoidales endoscópicos de los adenomas hipofisarios: una revisión crítica de nuestra experiencia

Resumen

Introducción: El abordaje quirúrgico de la región hipofisaria ha evolucionado desde las vías transcraneales, a las sublabiales y transeptales microscópicas hasta los abordajes endoscópicos actuales.

Objetivos: El objetivo de este trabajo es exponer y reflexionar sobre nuestra experiencia en el abordaje transnasal transesfenoidal endoscópico de los tumores hipofisarios, con las modificaciones que hemos introducido para mejorar la exéresis del tumor y disminuir la iatrogenia.

Material y métodos: A lo largo de 9 años hemos intervenido a 37 pacientes afectados de adenomas hipofisarios mediante abordaje transesfenoidal endoscópico. Utilizamos lentes de 0 y 30 grados, navegador óptico, instrumental habitual de endoscopia nasal y brazo articulado para fijación de la óptica en el tiempo neuroquirúrgico. Se accede a la celda hipofisaria mediante esfenoidotomía bilateral.

Resultados: La neumatización esfenoidal ha sido suficiente en todos los pacientes. Las complicaciones postoperatorias más frecuentes han sido la diabetes insípida y los trastornos endocrínicos. Rinoliquorrea postoperatoria en un paciente. Secuela nasal definitiva ninguna. Tiempo medio de estancia hospitalaria 5 días.

Conclusiones: El abordaje endoscópico guiado con el navegador aporta grandes ventajas: rapidez, seguridad, disminución de la iatrogenia, preservación de la vía aérea nasal. La resección de un fragmento de tabique nasal adyacente al rostrum mejora la manejabilidad de los instrumentos hacia los márgenes tumorales. La fijación del endoscopio estabiliza la visión y permite al segundo cirujano ayudar con más eficacia.

© 2010 Elsevier España, S.L. Todos los derechos reservados.

Introduction

Pituitary adenomas are the most common intracranial tumours, representing approximately 15% of the total.¹ Their clinical presentation depends on whether the tumour is secretory (less common) or non-secretory (more common). Among the secretory, the most common are those that produce prolactin, followed by those that produce growth hormone, adrenocorticotrophic hormone, FSH and luteinizing hormone.² Non-secretory adenomas are manifested by their mass effect. The clinical symptoms may include one or more of the following: endocrine disorder, headache, hypopituitarism, loss of vision, visual field defects and deficits in cranial nerves.³

With the exception of prolactinoma, the treatment of choice is surgical excision. Initially, the approach for pituitary tumours is the transcranial route, with high mortality rates. For this reason, we have sought other extracranial approach paths.⁴ In 1909, Cushing described the sublabial-transseptal-transsphenoidal route. However, it was Guiot, with the introduction of intraoperative fluoroscopy, and Hardy, with the surgical microscope, who standardised the technique.⁵ Transseptal routes and, subsequently, transthemoidal ones have also been used in recent times.⁶ The evolution of approaches to the pituitary fossa has continued in parallel to endonasal surgery. For this reason, the endoscopic endonasal transsphenoidal approach is now catching on, because it minimises intranasal complications and provides superior visualisation. The pneumatization of

the sphenoid sinus is a condition that needs to be evaluated for this approach.⁷

As in other hospitals, we began collaborating with neurosurgeons in 1998, first using the sublabial approach, continuing on with the transnasal-transseptal (microscopic) approaches,⁵ until we began to use the endoscopic transnasal approach in the year 2000. The aim of this article is to present our experience with the endoscopic transnasal transsphenoidal approach for pituitary tumours, with the modifications we have introduced to improve tumour removal of and reduce iatrogenic results: resection of 1 cm of the nasal septum attached to the sphenoid rostrum and fixing of the endoscope by an articulated arm in the neurosurgical surgery.

Material and methods

We conducted a retrospective study of 37 patients (19 men and 18 women) who had undergone operations for pituitary adenomas between January 2000 and May 2009. All of them had been intervened using the endoscopic transnasal transsphenoidal approach, conducted jointly by an otolaryngologist and a neurosurgeon. The age range was 35-95 years, with a mean age of 64.14 years. Depending on the size, we classified them into macroadenoma (more than 1 cm) and microadenoma (less than 1 cm). Only 5 were secretory. In two patients the diagnosis was coincidental and the rest presented symptoms (Table 1).

Table 1 Variety of clinical manifestations present at the time of diagnosis (37 patients in total)

Symptoms	Patients
Visual loss	18
Headache	16
Asthenia	4
Impotence	3
Acromegaly	3
Dizziness	3
Diplopia	2
Ophthalmoplegia	2
Amenorrhea	1
Weight increase	1
Galactorrhea	1
Gynaecomastia	1
Asymptomatic	2

The preoperative evaluation included an endocrine and ophthalmic study, nasal examination and imaging tests (magnetic resonance imaging [MRI] and computed tomography [CT]). The MRI indicated the extent of the tumour and CT informed us of pneumatization of the sphenoid sinus, as well as of the intersinus septum situation and/or other anatomical changes to the nasal sinus and fossae. We classified the sphenoid pneumatization as: conchal, sellar, presellar and postsellar.⁷

Surgical technique

We used 4mm rigid optics of 0 degrees for the initial approach and of 30 degrees for the complete tumour resection within the pituitary cell. As the topographic locator, we began with the image intensifier and, since 2005, have used the Surgimetric optical navigator (Navimetric, Valencia,

Spain), which requires cranial fixation by a Mayfield clamp (Integra LifeSciences Corporation, Cincinnati, USA). The otolaryngologist and the neurosurgeon worked closely and in combination.

The surgical steps were the following:

Otolaryngology Work

- Nasal vasoconstriction through lentinan contained in a mixture of 10cc of benzocaine at 4% plus 1cc of epinephrine at 1/100,000.
- Exploration of the nasal cavity, lateral dislocation of the middle and upper turbinates and location of the sphenoid ostium, using the choanal arch and the superior turbinate as references. Coagulation of the septal branch of the sphenopalatine artery to lower the anterior wall of the sinus without bleeding. This manoeuvre facilitates the removal of the anterosuperior extensions of the macroadenomas. The approach was conducted between the middle turbinate and the nasal septum.
- Opening of the anterior wall of both sphenoid sinuses by Laminotome from the ostium in an inferomedial direction through the corresponding fossae, until the bottom of the sphenoid is exposed.
- Resection of 1 cm of bony nasal septum adjacent to the anterior wall of the sphenoid sinus and the sphenoid rostrum by milling, until the bottom of the sinus is levelled.
- Resection of intersinus septum.
- Location of the bottom of the sella turcica and opening using drill and Laminotome.
- Exposure of the dura mater of the pituitary.

From this surgical step, the approach is combined: optics are introduced through the left nostril and are held and stabilised by the Unitrac pneumatic swivelling clamp (Aesculap, Tuttlingen, Germany). The neurosurgical instruments for tumour resection are inserted through the right nostril (Figure 1).

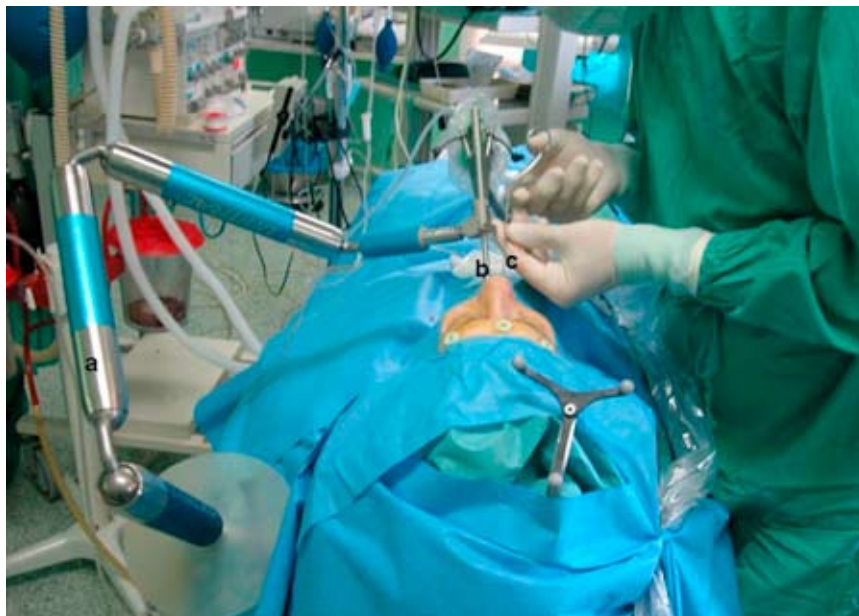

Figure 1 Layout of the surgical field: a) Unitrac articulated arm; b) optics; c) surgical instruments.

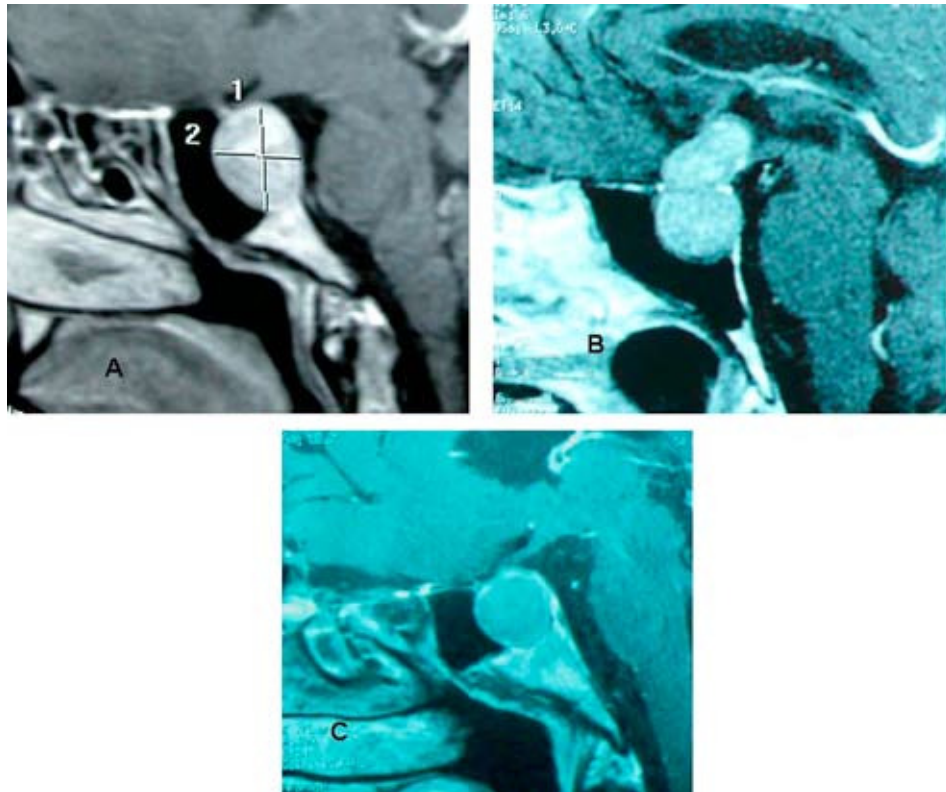


Figure 2 Types of sphenoid pneumatization in our patients. A) Sellar pneumatization 19% B) Postsellar pneumatization 54% C) Presellar pneumatization 27%.

Neurosurgery work

The fixing provided by the Unitrac arm stabilises the operative field visualisation and allows this step to be carried out comfortably by the neurosurgeon. The otolaryngologist works with the aim of achieving an optimal view, by rinsing and aspiration.

- Coagulation and opening of the dura mater by a cold surgical scalpel.
- Non-traumatic adenoma excision by pituitary spoons and tongs. The progressive and spontaneous decrease of the tumour due to the intracranial pressure facilitates its complete removal.
- Exploration of different angles of the pituitary fossa through the 30 degree lens to find potential tumoral residues.
- Excision of the tumoral residues identified. There is an attempt to preserve the *diaphragma sella*, as its injury is accompanied by an immediate, plentiful leak of cerebrospinal fluid (CSF).

The closure of the sella turcica is performed with Durag® and biological glue. In case of intraoperative CSF leakage, this closure is completed with abdominal fat, partially filling the sphenoid sinus, and with a new layer of biological glue. A nasal packing is placed and maintained for 3 days, along with antibiotic prophylaxis (amoxicillin/ clavulanate, 1 g iv every 8 hours), during which the patient should remain in bed with the headboard raised 30°. The usual hospital stay was 5 days.

Results

The most frequent sphenoid pneumatization was the postsellar (20 patients, 54%), followed by presellar (10 patients, 27%) and sellar (7 patients, 19%) (Figure 2). We found no patients with a conchal sphenoid.

Only one case of microadenoma was found. The other 36 were macroadenomas, 13 of which presented involvement of the cavernous sinus: bilateral in 7 cases and unilateral in 6.

In 2 patients the diagnosis was coincidental and the rest presented symptoms, which are shown in Table 1. Only 5 were secretory: 1 case secreting ACTH, 3 cases secreting growth hormone and 1 case secreting prolactin.

In 8 (21.62%) cases, it was necessary to perform a septoplasty in the same operation to reach the sphenoid recess appropriately. The only cases that were significant for this approach were deviations or spurs that affected the passage of the middle turbinate-nasal septum. The sphenoid ostia were located in 100% of the cases.

The neuronavigator, available in our hospital since 2005, was used as a support to surgery in 64.86% of patients. Before that, we used radioscopy.

In 7 patients (18.91%), there was an intraoperative CSF leak, directly related to a pituitary diaphragm lesion. In 6 cases, this was resolved in the same operation through the closure described previously, while one case required secondary surgery, 7 days after the initial operation.

The most common immediate surgical complication was diabetes insipidus (16 patients, 43.24%), which was transient

Table 2 Postoperative complications (37 patients in total)**Immediate postoperative complications**

<i>Diabetes insipida</i>	16 patients
<i>CSF fistula</i>	1 patient
<i>Suprarenal failure</i>	1 patient

Late postoperative complications

<i>Pituitary apoplexy</i>	1 patient
<i>Hormonal deficits</i>	26 patients
Panhypopituitarism	13 patients
Deficit of ACTH-TSH	4 patients
Deficit of ACTH	4 patients
Deficit of gonadotropin	1 patient
Deficit of TSH-gonadotropin	2 patients
Deficit of ACTH-TSH-gonadotropin	2 patients

Rhinology complications

<i>Transitory epistaxis</i>	3 patients
<i>Transitory rhinitis with crusts</i>	2 patients
<i>Synechia of nasal fossae</i>	1 patient

in all cases. Additionally, as an immediate manifestation, we observed postoperative adrenal insufficiency in one patient (Table 2).

Subsequent neurosurgical MRI controls showed that 15 patients (40.54%) were free of macroscopic lesions. In 22 patients (59.45%), there was some tumoral residue. Of these, the residue was of more than 1 cm in 16/22. To date, tumour growth has been observed in 6/22 patients, and 5 of them were reoperated, with one of them receiving radiation therapy.

Late complications: one patient (2.7%) suffered pituitary apoplexy 9 years after being intervened. A total of 26 patients (70.2%) required hormonal replacement therapy after surgery; 13 (50%) of them presented panhypopituitarism. Deficits of ACTH-TSH and ACTH were the second most frequent complication, with each combination appearing in 4 patients. Other less common deficits included gonadotropin, TSH-gonadotropin and ACTH-TSH-gonadotropin. Vision improved after surgery in 9 (50%) of the 18 patients with preoperative visual loss (Table 2).

Only 6 (16.21%) patients presented postoperative nasal discomfort: epistaxis in 3 and crusty rhinitis in 2, both transient. The other patient complained of mild nasal obstruction, which was associated with synechia, without requiring surgical treatment (Table 2).

Discussion

The preoperative imaging study of the sphenoid sinus and the exploration of the nasal fossae were essential to guide the access path and schedule a septoplasty or other intraoperative anatomical correction if necessary.⁸ All surgical instruments were passed between the middle meatus and the nasal septum, so that only deviations

affecting these structures needed to be corrected. A total of 8 intraoperative septoplasties were performed on our patients, without interfering with the surgery, except during the few minutes they lasted. Good exposure of the pituitary cell was essential to achieving adequate resection of the adenoma,³ and this also depended on the pneumatization of the sphenoid. It is therefore important to emphasise that the sphenoid pneumatization was sufficient to enable access to the sella turcica in all cases. Quickly localising the sphenoid ostium generated a rapid, safe approach route.

The use of the neuronavigator reduced operating time and facilitated surgery. It eliminated all the drawbacks entailed by radiology equipment in the operating room, but, above all, its three-dimensional image provided a more secure and accurate orientation while allowing us to work with real-time images.⁴

Incomplete excision of the tumour was somewhat higher than in some patient series¹⁰ and similar to others.¹¹ The learning curve had a significant influence on this parameter.^{3,12} However, we think that large tumour size was more significant in our case, given that 13 patients (37%) had cavernous sinus involvement that made complete excision more difficult.

The main complications, as in other series,^{9,10} were endocrine disorders, which occur similarly in other approaches.¹³⁻¹⁵ In Spanish series of pituitary adenoma surgery by microsurgical and endoscopic route, these complications reach 54%.¹¹ In our case, total hormone deficiencies (panhypopituitarism) affected 37% of patients and partial deficiencies another 37% (Table 2).

We highlight the lack of serious complications, such as intracranial involvement, optic nerve lesions, lesions of other cranial nerves and haemorrhaging. Also noteworthy is the fact that 50% of patients suffering prior visual loss improved after tumour resection.

From the otorhinolaryngology standpoint, preservation of the nasal airway was the norm. Although the goal of surgery was to remove the tumour, the sequelae on the nasal route, in the form of obstruction, atrophic rhinitis and/or anosmia, are very important for the patient.¹⁶ Preserving a fully functional nose should be, in our opinion, a fundamental goal in any neurosurgical transnasal approach.

Postoperative CSF leak occurred in only one patient and required surgical review. We believe that the closure of the bottom of the sella turcica that we carried out was sufficient, without the need for pedicled nasal mucosa flaps.^{17,18}

Approaching both sphenoids through both nostrils (optics through one nostril and remaining instruments through the other) was essential in providing an adequate view.³ Excision of a 1cm piece of nasal septum adjacent to the nostrum facilitated orientation, layout and management of instruments within the pituitary fossa. Likewise, fixing the endoscope through the Unitrac articulated arm stabilised the operative field and made handling of the vacuum or other instruments easier for the second surgeon, thus optimising tumour resection.

Although comparison with other approaches was not the aim of this work, the literature reports^{13,15,19} (and we also believe) that the endoscopic approach is faster, entails less blood loss, less pain, shorter postoperative stay and fewer complications. Endoscopic view of the pituitary fossa

with endoscopes of 0 and 30 degrees makes it possible to identify tumoral residues, which would not be so with a microscope. In addition, it provides an overview of the limiting anatomical landmarks.^{3,13}

Conclusions

We conclude that the endoscopic transnasal approach for pituitary adenomas provides significant benefits: minimum nasal trauma with bilateral sphenoidotomy; the endoscope provides a panoramic view that prevents iatrogenic results; the combination of optics with 0 and 30 degrees enables hidden tumoral residues to be discovered; all nasal functions are preserved; and postoperative and perioperative rhinological complications are reduced.

Conflict of interest

The authors declare no conflict of interest.

References

1. Sanno A, Teramoto A, Osamura RY, Horvath E, Kovacs K, Lloyd RV, et al. Pathology of pituitary tumors. *Neurosurg Clin N Am*. 2003;14:25-39.
2. Otori N, Haruna S, Kamio M, Ohshi G, Moriyama H. Endoscopic transethmosphenoidal approach for pituitary tumours with image guidance. *Am J Rhinol*. 2001;15:381-6.
3. Wormald PJ. Cirugía endoscópica nasosinusal. Anatomía, reconstrucción tridimensional y técnica quirúrgica. 2nd ed. Thieme Medical Publishers, Inc; 2010.
4. Liu JK, Weiss MH, Couldwell WT. Surgical approaches to pituitary tumors. *Neurosurg Clin N Am*. 2003;14:93-7.
5. Díaz A, Armengot M, Alba JR, Barcia JA, Basterra J. Abordajes transnasales para los tumores de región hipofisaria. Nuestra experiencia. *Acta Otorrinolaringol Esp*. 2003;54:419-24.
6. Wilson CB. A decade of pituitary microsurgery: The Herbert olivecrona lecture. *J Neurosurg*. 1984;61:814-33.
7. Lang J. Bases anatómicas de las fosas nasales y de los senos paranasales. In: Bernal M, Massegur H, Sprekelsen C, Ademá JM, Horacio H, Fabra JM, editors. Cirugía endoscópica nasosinusal. Girona: Gràfiques Alzamora, SA; 2001. p. 17-57.
8. Lubbe D, Semple P. Pre-operative assesement of patients undergoing endoscopic, transnasal, transsphenoidal pituitary surgery. *J Laryngol Otol*. 2008;122:644-6.
9. Enseñat J, Quesada JL, Aparicio J, Pámies C, Barber X, Topczewski T, et al. Comparación del abordaje sublabial transesfenoidal microquirúrgico frente endonasal transesfenoidal endoscópico. Estudio prospectivo de 50 pacientes. *Neurocirugía*. 2009;20:335-45.
10. Sandoval JH, Flores F, Vargas MC, Páez JM. Complicaciones del abordaje endonasal directo transesfenoidal en el manejo de adenoma de hipófisis. *Neurocirugía*. 2007;18:485-91.
11. Civantos Modino S, Montaña Martínez J, López Serrano R, Díaz Guardiola P, Guijarro De Armas G, Gómez Angulo JC, et al. Casuistry review of patients undergoing surgery for pituitary adenomas in Getafe University Hospital (Spain). *Endocrinol Nutr*. 2010 Jun 22. [Epub ahead of print].
12. Sonnenburg RE, White D, Ewend MG, Senior B. The learning curve in minimally invasive pituitary surgery. *Am J Rhinol*. 2004;18:259-63.
13. Higgins TS, Courtemanche C, Karakla D, Strasnick B, Singh RV, Koen JL, Han JK. Analysis of transnasal endoscopic versus transeptal microscopic approach for excision of pituitary tumors. *Am J Rhinol*. 2008;22:649-52.
14. Neal JG, Patel SJ, Kulbersh JS, Osguthorpe JD, Schlosser RJ. Comparison of techniques for transsphenoidal pituitary surgery. *Am J Rhinol*. 2007;21:203-6.
15. Shah S, Har-El G. Diabetes insipidus after pituitary surgery: incidence after traditional versus endoscopic transsphenoidal approaches. *Am J Rhinol*. 2001;15:377-9.
16. Zada G, Kelly DF, Cohan P. Endonasal transsphenoidal approach for pituitary adenomas and other sellar lesions: an assesment to efficacy, safety, and patient impressions. *J Neurosurg*. 2003;98:335-8.
17. Harvey RJ, Sheahan PO, Schlosser RJ. Inferior turbinate pedicle flap for endoscopic skull base defect repair. *Am J Rhinol Allergy*. 2009;23:522-6.
18. Hadad G, Bassagasteguy I, Carrau RL, Mataza JC, Kassam A, Shydelman CH, et al. A novel reconstructive technique after endoscopic expanded endonasal approaches: vascular pedicle nasoseptal flap. *Laryngoscope*. 2006;116:1882-6.
19. Rotenberg B, Tam S, Ryu WH, Duggal N. Microscopic versus endoscopic pituitary surgery: a systematic review. *Laryngoscope*. 2010;120:1292-7.