



CASE STUDY

Extramedullary Plasmacytoma as an Exceptional Location in Frontal Sinus[☆]

Plasmocitoma extramedular como localización excepcional en seno frontal

Beatriz Ágreda Moreno,^{*} Ángel Urpegui García, Andrés López Vázquez, Héctor Vallés Varela

Servicio de Otorrinolaringología, Hospital Clínico Universitario Lozano Blesa, Zaragoza, Spain

Received 25 July 2011; accepted 21 February 2012

Clinical Case

We present the case of a 64-year-old woman who came to Emergency Services with a left frontal mass that was painful when palpated. The mass had a history of 3 days, lacking affection of ocular motility and nasal symptoms. With the diagnostic suspicion of frontal mucocele, she was admitted to begin antibiotic treatment. In the CT performed, the image showed mainly left frontal occupation with notable bone erosion, along with disruption of the diploic inner table and extension towards ethmoid cells and left orbit (Fig. 1).

Faced with the tumour size and aggressiveness, we chose to perform surgery using an external frontal approach; we found a friable bluish-grey tumour mass, affecting both the inner and external tables of the frontal bone, and which was fistulised towards the left orbit (Fig. 2). The apparently unaffected dura mater was seen through the bone

defect in the inner table of the frontal sinus. The extemporary biopsy reported malignant tumour lesion. Macroscopic resection was performed, without tumour-free margins of safety because of the orbital and cerebral extension of the tumour and the bone defects mentioned were closed with broad fascia and DuraGen.

The final postsurgical histopathological analysis revealed proliferation of plasma cells. Consequently, the patient was referred to the Haematology Service, which carried out the appropriate extension study. This study ruled out multiple myeloma, so we diagnosed the case as extramedullary plasmacytoma of the sinus. Radiotherapy treatment was then instituted and serial follow-ups were scheduled by the Haematology Service.

Discussion

Extramedullary plasmacytoma is a proliferation of monoclonal plasma cells located in an extraskeletal spot.¹ Its incidence is less than 1% in head and neck neoplasms^{2–4} and it is found in only 3% of all the tumours of plasma cells.^{2,5} It can appear in any soft tissue, but 80% are located in the upper airway (nasal cavity, nasal sinus, oropharynx and larynx).^{3,6,7} It affects males more frequently,⁴ with a 4:1 ratio, especially in the sixth to eighth decades of life.⁵

[☆] Please cite this article as: Ágreda Moreno B, Urpegui García Á, López Vázquez A, Vallés Varela H. Plasmocitoma extramedular como localización excepcional en seno frontal. Acta Otorrinolaringol Esp. 2013;64:374–376.

^{*} Corresponding author.

E-mail address: beagreda@hotmail.com (B. Ágreda Moreno).

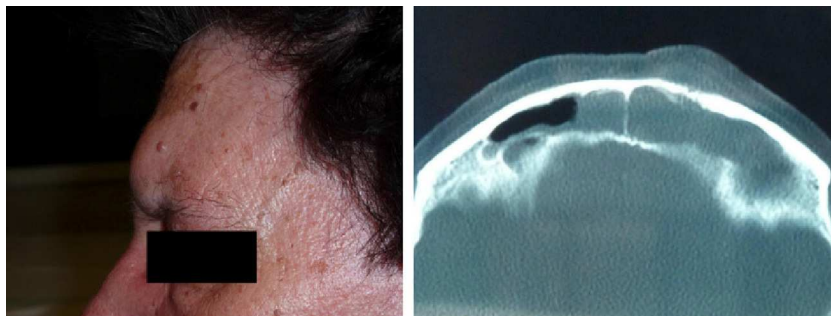


Figure 1 External appearance of the frontal mass, and its correspondence with the radiological image.

The cause of extramedullary plasmacytoma is still unknown. However, it is believed that it might affect the chronic stimulation or inhaled irritants, a viral infection, a radiation overdose or interactions of genes in the reticuloendothelial system.^{2,5}

Clinical manifestations vary based on location. If it is found in the nostrils, it can cause nasal obstruction, anosmia, headache and nosebleed.²⁻⁴ At orbital level it can cause diplopia, ptosis, decreased visual sharpness or altered ocular motility. It can also, as in the case of our patient, fail to cause any type of nasal or ocular symptoms, in spite of its location. It rarely produces dural affection or intracerebral extension.⁸

The CT image of extramedullary plasmacytoma is not specific; it is compatible with solid tumours of variable enhancement, with possible bone destruction, infiltration or displacement of adjacent structures.^{6,7} Macroscopically, you can see a mass of friable, polypoid soft tissue, with necrotic zones inside it.⁴

Histologically, it consists of a monomorphic proliferation of plasma cells. On occasion, it can produce some type of immunoglobulin, frequently IgG.

To reach a diagnosis, a complete systemic study should be carried out so as to rule out the presence of a multiple myeloma.^{4,5} To do this, protein electrophoresis is performed in blood and urine (ruling out the existence of immunoglobulins in them), along with a study of renal and hepatic function, biopsy of bone marrow and complete skeletal study with CT or PET scan.^{1,3,4} The existence of hypercalcaemia, renal insufficiency and anaemia should also be ruled out.⁶ If all of this is normal, it can be concluded that we have a solitary plasmacytoma, not a multiple myeloma.

Differential diagnosis should be done with sarcoma, squamous cell cancer, meningioma, haemangioma,

neurofibroma, esthesioneuroblastoma and lymphoma, among others.⁷

With respect to treatment, surgery is necessary to biopsy the lesion and to obtain a diagnosis. However, it does not need to be extremely aggressive, as the treatment of choice is radical radiotherapy, given that it is a highly radiosensitive tumour.^{4,5}

Strict follow-ups for these patients are very important: extramedullary plasmacytoma has a risk of recurrence of 22%, tendency to transformation into multiple myeloma of 15%–20%^{1,5} and the possibility of causing distance metastasis of 30%,^{1,5} which can occur several years after the initial diagnosis. With all of this, global survival is 70% at 10 years.^{6,8}

Although the majority of extramedullary plasmacytomas appear in the area of the upper airway, when one is found in the nasal sinus, the most frequently affected are the maxillary sinuses. We have found few publications that mention its location in the nasal sinus and none indicating placement exclusively in the frontal sinus. Consequently, we feel that this is an extremely rare case, which at first led us to consider frontal mucocoele.

As a conclusion, we can state that when faced with any mass in the nasal sinuses, a wide range of differential diagnoses should be kept in mind, even though some of them may be very rare. A diagnosis of one condition or another will lead to very different treatments. In this case, the extramedullary plasmacytoma is potentially curable. Consequently, once the diagnosis is established, the tumour should be treated with radical radiotherapy, ruling out extension to multiple myeloma, at which time chemotherapy and autologous bone marrow transplant would be the first option.

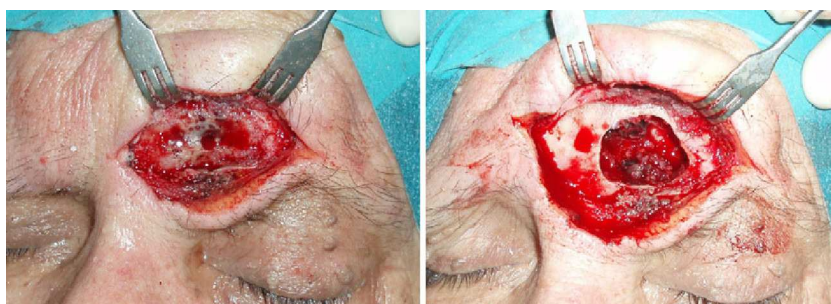


Figure 2 Two steps in the surgery. Bone affectation, and the macroscopic appearance of the mass, inside the frontal sinus can be seen.

Conflict of Interests

The authors have no conflicts of interests to declare.

References

1. Megat MAR, Jong YH, Primuharsa SHA. Extramedullary plasmacytoma in the maxillary sinus. *Singapore Med J.* 2008;49:e310-1.
2. Attanasio G, Viccaro M, Barbaro M, Seta E, Filipo R. Extramedullary plasmacytoma of paranasal sinuses. A combined therapeutic strategy. *Acta Otorhinolaryngol Ital.* 2006;26:118-20.
3. Paz I, Mercado V, Valdenegro JP, Krause F. Plasmocitoma extramedular en otorrinolaringología. *Rev Otorrinolaringol Cir Cab Cuello.* 2001;61:47-54.
4. García C, Armengot M, Sabater V, Rebol RM, Frías S, Basterra J, et al. Plasmocitoma solitario extramedular de amígdala tubárica. *Acta Otorrinolaringol Esp.* 2009;60:301-3.
5. Moshref M, Mashhadi F, Sargolzaei S, Nafarzadeh S. Extramedullary plasmacytoma of the gingiva. *Arch Iranian Med.* 2007;10:91-3.
6. Hoon S, Zoon Y, Hee E, Hong K. Endoscopic endonasal transsphenoidal resection of solitary extramedullary plasmacytoma in the sphenoid sinus with destruction of Skull base. *J Korean Neurosurg Soc.* 2009;46:156-60.
7. Cheng G, Chor-Sang J, Au WY, Khong P. Radiologic manifestations of primary solitary extramedullary and multiple solitary plasmacytomas. *AJR.* 2006;186:821-7.
8. Wein R, Popat S, Doerr T, Dutcher P. Plasma cell tumors of the skull base: four case reports and literature review. *Skull Base.* 2002;12:77-86.