



SCIENTIFIC LETTER

The MLG-R muscle injury classification for hamstrings. Examples and guidelines for its use



Clasificación de lesiones musculares MLG-R para los isquiotibiales. Ejemplos y directrices de uso

Introduction

Muscle injuries are very common in sport.^{1–3} In soccer, the most popular sport in the world, the majority of muscle injuries are located in the lower extremity (92–97%); hamstrings (28–37%), quadriceps (19–32%), adductors (19–23%), and calf muscles (12–13%),¹ all of them are biarticular muscles, with a complex architecture and containing a high proportion of fast-twitch fibers.¹

Football teams have important budgets and spend great amounts of money to win titles; it has been proved that injuries had a significant influence on performance in male professional football,⁴ but muscle injuries seem to keep growing.⁵ The reason to this is multivariable: there is no consensus regarding hamstring muscle injuries (HMI) return to play (RTP) criteria in the literature,⁶ the time for recovery is highly variable,⁷ the increased physical demands during games,⁸ or the influence of congested period of games on players health.⁹

During the last years several proposals for classification and grading muscle injuries have been published.^{10–12} The FC Barcelona medical department with the collaboration of two important institutions in sports medicine and several experts in the field, have developed the MLG-R proposal, with the hamstrings group as a model.¹³

A good classification system is necessary, which allows to have reliable epidemiological data, which are the base to improve our knowledge about muscle injuries; better knowledge leads to better therapeutic options, prognosis, RTP criteria or lower reinjury rates.

MLG-R description and goals of the paper

The MLG-R proposal is a four-letter initialism system (MLG-R), respectively referring to the mechanism of injury (M), location of injury (L), grading of severity (G), and number

of muscle re-injuries (R). The aim of the proposal was to describe a classification system for muscle injuries with easy clinical application, adequate grouping of injuries with similar functional impairment, and potential prognostic value (which still need to be proved). To achieve classification objectives, the study was designed in three phases: (1) identify the existing evidence related to risk and prognostic factors for muscle injuries; (2) discuss these factors between two of the institutions and establish a consensus based on the quality of studies in combination with experts' experience; and (3) elaborate the final classification.¹³

The extracellular matrix (ECM) has been classically described in three layers: endomysium, perimysium, and epimysium¹⁴; in our opinion ECM plays a key role in muscle injuries clinical symptoms and severity, because of that, we could say that the main aim of the proposal is oriented to evaluate how much ECM is being affected by the injury. The amount of damage to the ECM is influenced by the mechanism of injury (direct or indirect),¹⁵ the injury relationship with the MTJ (more proximal or distal to the MTJ insertion),^{16,17} the percentage of the muscle cross-sectional area (CSA)¹⁸ affected by the injury (degree of injury), and the presence of tendon involvement.¹⁹ To correctly use the MLG-R proposal a deep knowledge about muscles anatomy and its MTJs will be needed.

The fill out of the first letter will be easy, [Table 1](#). For a long-time muscle injuries were classified as direct (T as first letter in the proposal) or indirect (I)²⁰; the size of direct muscle injuries is not well correlated with clinical signs and functional impairment,²¹ and such injuries usually have a better evolution with a shorter time to recovery in comparison to indirect injuries.¹⁵ In our opinion, this is because the injury is the consequence of an external compression causing mainly a damage to the contractile fibers of the muscle, however the connective tissue remains well preserved in most of the cases, therefore the muscle function is less affected. When an indirect muscle injury occurs the damaging force is created and transmitted through the muscle connective tissue causing an injury to the connective tissue itself or in the borders between the connective tissue and the contractile fibers, this type of injury is worse tolerated causing more functional impairment.¹⁵

The second letter will give the information about the anatomical location of the injury, at the proximal (P), middle (M) or distal (D) third of the thigh, and what is even more important, the subindex describing if the injury is located

Table 1 Summary of the new classification system.

Mechanism of injury (M)	Locations of injury (L)	Grading of severity (G)	Number of muscle re-injuries (R)
<i>Hamstrings direct injuries</i>			
T (direct)	P Injury located in the proximal third of the muscle belly	0–3	0 1st episode
	M Injury located in the middle third of the muscle belly		1 1st re-injury
	D Injury located in the distal third of the muscle belly		2 2nd re-injury, and so on.
<i>Hamstrings indirect injuries</i>			
I (indirect) plus subindex s for stretching-type, or subindex p for sprinting-type.	P Injury located in the proximal third of the muscle belly. The second letter is a subindex p or d to describe the injury relation with the proximal or distal MTJ respectively.	0–3	0 1st episode
	M Injury located in the middle third of the muscle belly, plus the corresponding subindex.		1 1st re-injury
	D Injury located in the distal third of the muscle belly, plus the corresponding subindex.		2 2nd re-injury, and so on.
<i>Negative MRI injuries (location is pain related)</i>			
N plus subindex s for indirect injuries stretching-type, or subindex p for sprinting-type.	N p proximal third injury	0–3	0 1st episode
	N m middle third injury		1 1st re-injury
	N d distal third injury		2 2nd re-injury, and so on.
<i>Grading of injury severity</i>			
0	When codifying indirect injuries with clinical suspicion but negative MRI, a Grade 0 injury is codified. In these cases the second letter describes the pain locations in the muscle belly.		
1	Hyperintense muscle fibers edema without intramuscular hemorrhage or architectural distortion (fiber architecture and pennation angle preserved). Edema pattern: interstitial hyperintensity with feathery distribution on FSPD or T2 FSE + STIR images.		
2	Hyperintense muscle fibers and or peritendon edema with minor muscle fibers architectural distortion (fiber blurring and/or pennation angle distortion) ± minor intermuscular hemorrhage, but no quantifiable gap between fibers. Edema pattern, same as for grade 1.		
3	Any quantifiable gap between fibers in craniocaudal or axial planes. Hyperintense focal defect with partial retraction of muscle fibers ± intermuscular hemorrhage. The gap between fibers at the injury's maximal area in an axial plane of the affected muscle belly should be documented. The exact %CSA should be documented as a subindex to the grade.		
r	When codifying an intra-tendon injury or an injury affecting the MTJ or intramuscular tendon showing disruption/retraction or loss of tension exist (gap), a superscript (r) should be added to the grade.		

around fibers from the proximal (p) or distal (d) MTJ.¹³ In injuries located more distal to the MTJ origin, less amount of connective tissue will be damaged.¹⁶ As we mentioned before, a deep knowledge about the muscle, specially about the MTJ anatomy is needed, because you can have an injury located in the distal third of the thigh but affecting fibers from the more distal part of the proximal MTJ tendon, and the prognosis will be totally different than a distal third injury located around fibers of the distal MTJ.

The third letter is the grade of the injury, and it is defined by several radiologic features; the interstitial edema presence or absence (T2 feathery hyperintensity), architectural fibers distortion (muscular fiber blurring, gap between muscular fibers, loss of pennation angle), injury of the connective tissue (T2 hyperintensity and tears), intramuscular hematoma and intermuscular fluid.¹³

Grades 1 and 2 are defined by edema presence, no quantification, and its characteristics (Table 1). The grade

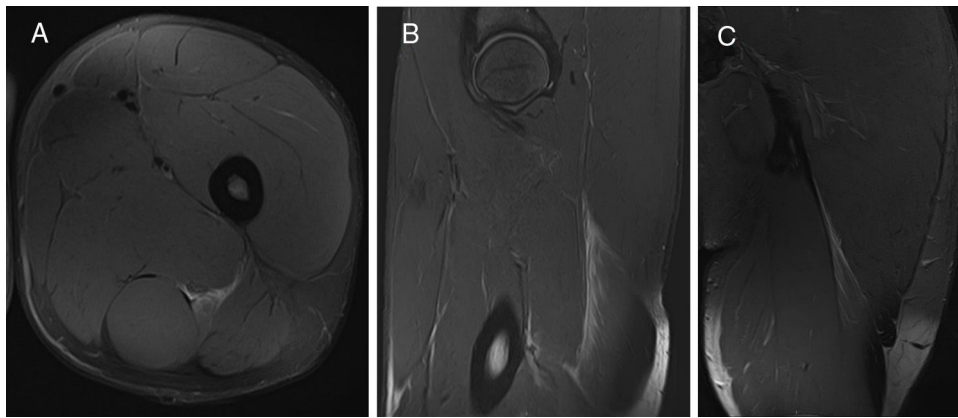


Figure 1 Biceps femoris long head (BFLh) indirect injury (I), located at the proximal third of the thigh (P) and affecting the proximal MTJ (P_p). There is hyperintense focal defect with partial retraction of muscle fibers \pm intermuscular hemorrhage (G_3). This is a first episode (R_0). A: Axial T2 weighted fat saturated image showing MTJ destructured with interstitial edema and intermuscular fluid. B: Sagittal T2 weighted fat saturated image showing hyperintense focal defect with partial retraction of muscle fibers. C: Coronal T2 weighted fat saturated image showing intermuscular hemorrhage. Final codification: I P_p G_3 R_0 .

3 use the %CSA to evaluate the amount of injury, for that we use the axial MR slice where we see the biggest area of injury, and we obtain the quotient between this region and the global area of the muscle belly at this level¹⁸; it will be documented as a subindex in the grade.

It has been reported that muscle injuries affecting the intramuscular tendon require a prolonged rehabilitation time and may have higher recurrence rates.^{16,19} Because of that, in our proposal, tendon injuries will be recorded as a superindex in the third letter (Grade); if an intratendon injury or an injury affecting the MTJ or intramuscular tendon showing disruption/retraction or loss of tension exist (gap), a superscript (r) should be added to the grade.

The fourth letter fill out will describe if we are talking about a first episode of muscle injury, or a reinjury, and if this is the case, the number of reinjury.

The aim of this paper is to describe how is the process to use the MLG-R proposal is. For that we will codify injuries using several examples of muscle injuries in hamstrings to describe the process. The full description of the MLG-R proposal and the meaning of each letter has been described in a previous paper¹³; it is also summarized in the [Table 1](#) in this paper.

Examples of injuries and codification

[Figs. 1 and 2](#), BFLh proximal MTJ injuries.

[Fig. 3](#), BFLh distal MTJ.

[Figs. 4 and 5](#), semimembranosus proximal and distal MTJ injuries.

[Fig. 6](#), semitendinosus proximal MTJ injury.

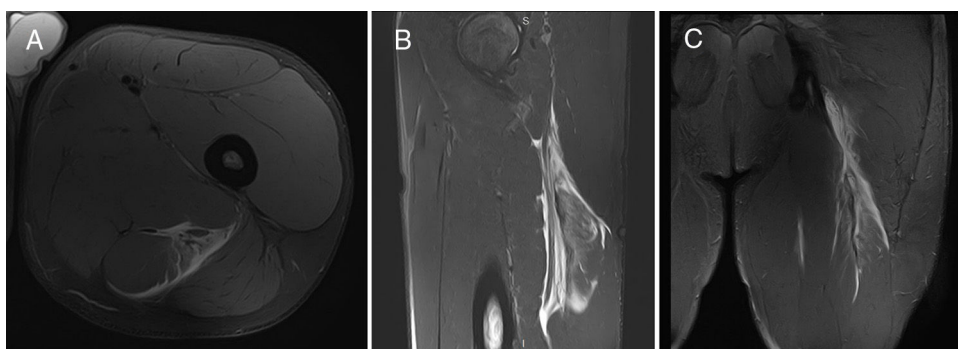


Figure 2 Biceps femoris long head (BFLh) indirect injury (I), located at the proximal third of the thigh and affecting the proximal MTJ (P_p). There is quantifiable gap between muscle fibers in craniocaudal and axial planes; hyperintense focal defect with retraction and intermuscular hemorrhage (G_3); there is also a clear transversal free tendon injury tendon showing disruption, retraction and loss of tension, superscript r (Gr_3). This is a first episode (R_0). A: Axial T2 weighted fat saturated image showing intermuscular hemorrhage surrounding the sciatic nerve, and a free tendon rupture and injury of the semitendinosus MTJ whit interstitial edema. B: Sagittal T2 weighted fat saturated image showing loss of the pennation angle and intermuscular fluid. C: Coronal T2 weighted fat saturated image showing central tendon loss of tension. Final codification: I P_p Gr_3 R_0 .

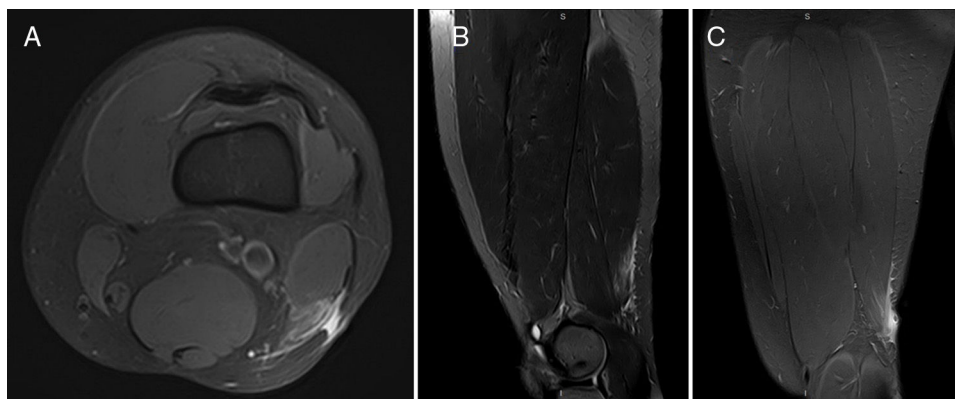


Figure 3 Biceps femoris long head (BFlh) indirect injury (I), located at the distal third of the thigh and affecting the distal MTJ (Dd). There is hyperintense focal defect with partial retraction of muscle fibers \pm intermuscular hemorrhage (G3); the tendon is affected but there is not disruption/retraction or loss of tension exist (no r superscript). This is a first episode (R0). A: Axial T2 weighted fat saturated image showing distal tendon injury and interstitial edema of the BFlh. B: Sagittal T2 weighted fat saturated image showing tendon injury but without retraction or loss of tension, therefore no superscript (r) should be added to the grade. C: Coronal T2 weighted fat saturated image showing interstitial muscular edema. Final codification: I Dd G3 R0.

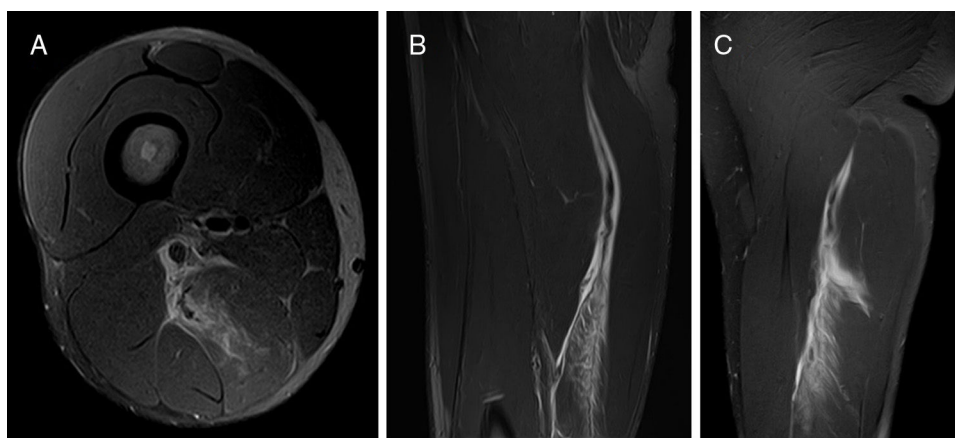


Figure 4 Semimembranosus (SMB) indirect injury (I), located at the proximal third of the thigh and affecting the proximal MTJ (M/Pp). There is quantifiable gap between muscle fibers in craniocaudal and axial planes; hyperintense focal defect with retraction and intermuscular hemorrhage (G3); there is also a clear transversal/longitudinal? tendon injury tendon showing disruption, retraction and loss of tension, superscript r (Gr3). This is a first episode (R0). A: Axial T2 weighted fat saturated image showing MTJ disruption whit interstitial edema; there are chronic changes affecting the tendon. B: Sagittal T2 weighted fat saturated image showing tendon loss of tension, and interstitial edema. C: Coronal T2 weighted fat saturated image showing again the tendon loss of tension and loss of the muscle fibers pennation angle. Final codification: I M/Pp Gr3 R0.

Discussion

Having reviewed the most relevant muscle injury classification systems we can see some differences between them. The proposal from Chan¹⁰ was the first including the injury's anatomical location using the connective tissue and the injury patterns to describe a muscle injury; both were important improvements, specially including the connective tissue anatomy to describe the injury location. The problem in terms of describing the injury patterns is common to other proposals, there is a lack of consensus about the terminology, which means a great subjectivity when injuries have to be described. A key point in any classification should be

the use of clear, non-ambiguous terminology. "Myofascial" is a term widely used, representing a particular injury location with a different clinical evolution and prognosis,^{16,17,22} but it is an ambiguous term, and other expressions such as "peripheral"²³ or "myoaponeurotic"²⁴ have been suggested and used to describe similar injuries. To avoid this subjectivity, the MLG-R proposal is to describe the anatomical location of the injury and its relation to the MTJ, injuries located more "peripheral" to the MTJ insertion will have a better prognosis.

The Munich consensus¹¹ was a great effort trying to include all types of muscle injuries, offering a wide range of possibilities to classify and grade them. The inclusion of

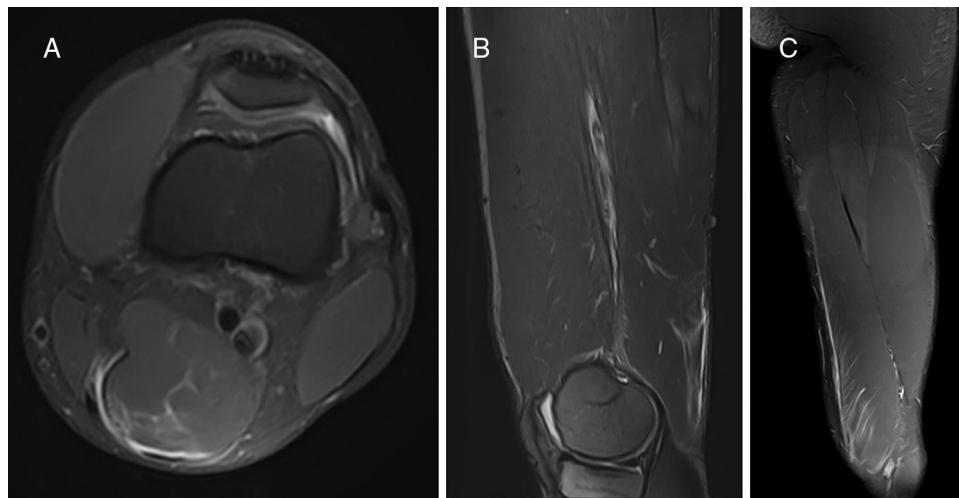


Figure 5 Semimembranosus (SMB) indirect injury (I), located at the distal third of the thigh and affecting the distal MTJ (Dd). There is quantifiable gap between muscle fibers in craniocaudal and axial planes; hyperintense focal defect with retraction and intermuscular hemorrhage (G3). This is a first episode (R0). A: Axial T2 weighted fat saturated image showing MTJ destructuration. B: Sagittal T2 weighted fat saturated image showing MTJ destructuration without loss of tension. C: Coronal T2 weighted fat saturated image showing interstitial edema. Final codification: I Dd G3 R0.

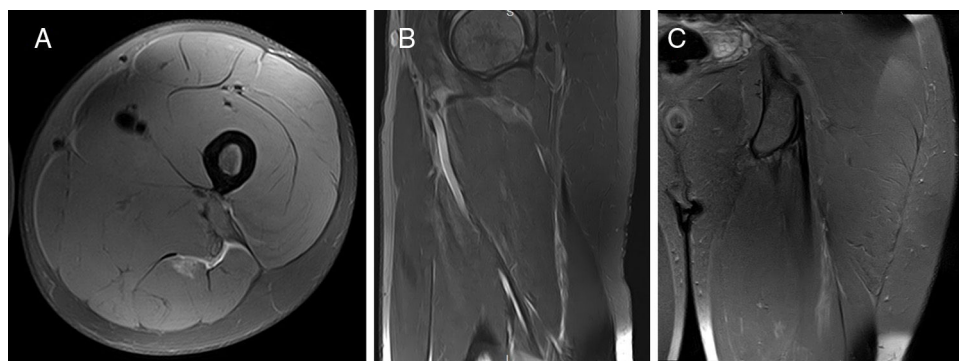


Figure 6 Semitendinosus (SMT) indirect injury (I), located at the proximal third of the thigh and affecting the proximal MTJ (Pp). There is quantifiable gap between muscle fibers in craniocaudal and axial planes; hyperintense focal defect with retraction and intermuscular hemorrhage (G3). This is a first episode (R0). A: Axial T2 weighted fat saturated image showing muscle fibers destructuration and intermuscular fluid. B: Sagittal T2 weighted fat saturated image showing the MTJ injury with small muscle fibers gap. C: Coronal T2 weighted fat saturated image showing interstitial edema. Final codification: I Pp G3 R0.

delayed onset muscular soreness (DOMS) as a muscle injury is quite controversial. Several publications have proved that DOMS is an adaptive process far from being considered a muscle injury, even when histologically some features are similar in both diagnosis.²⁵ While histological disturbances might be present, their origin appears related to intense activity for which the muscle is unprepared.²⁵ Also the definition of functional or non-structural disorders, as other authors have pointed out, functional disorders related to muscle injuries require further investigation to be better understood.²⁶ It should be taken into account that the diagnosis of muscle distortion is not yet well understood and remains subjective, which makes the acquisition of solid epidemiological data difficult.

Although one of the main goals of our proposal was to enhance communication between healthcare and sports-related professionals by avoiding the use of confusing terminology, the MLG-R proposal has been criticized because

of the complexity of nomenclature used, which can cause limited attractiveness for its use amongst the sports community.²⁷ As it has been proved in the previous examples, the use of our classification proposal is very easy to understand and acquire, although a deep knowledge of muscle anatomy is required for the proper use of the classification. With the fill out of the four letters, the classification proposal includes: a description of the injury with information about how it occurs, where the injury anatomically located is, and its relationship with the myotendinous junction (MTJ) of the muscle. The previous items will offer a description about how severe the injury is by quantifying the amount of connective tissue affected, and then we will add the chronology of the injury (first episode or reinjury), offering a full description of the injury and its timing evolution.

The MLG-R classification system has been recognized as the first to incorporate the re-injury status into the grading

of muscle injuries²⁷; re-injuries are known to cause significant longer absences,¹ therefore to have influence in prognosis and be taken in account for the RTP. To incorporate the re-injury status offers important information about the injury, helping to understand the history and to better foresee its evolution.

The grading category, is based on the muscle injury radiological features. All these features are globally evaluated and the quantification of edema is not a parameter taken into account. The most important thing is to evaluate the connective tissue injured.

There is currently no objective data to establish a cut-off point for the grade of muscle injury with a good prognostic value. Therefore, all injuries with a measurable gap would be coded as grade 3 and the corresponding % CSA would be recorded and added as a sub-index, in order to evaluate in the future is changes at this point are needed, and more grades established.

The definition of re-injury is any indirect muscle injury affecting the same MTJ, its intramuscular tendon or fibers associated with it (even in a different location) during the next two months after the RTP.¹³ It is important to establish the period of time when it can be considered a reinjury, it is well known that most reinjuries occur during the first 2–3 months after RTP then they decrease drastically. As an example, if the first injury of the long head of biceps femoris affects the proximal MTJ in the proximal third of the muscle belly and another injury occurs within the next 2 months but located in the middle third of the muscle belly in fibers related to the proximal MTJ, this would be considered as a re-injury. By contrast, if the second injury is located around or affecting the distal MTJ (a different MTJ from the initial injury), it would not be considered a re-injury.

The MLG-R is not the best and it will not be the last proposal, but its strongest point is to be a flexible and open system, allowing future adaptation to incorporate any subsequent knowledge shown to be relevant to prognosis or diagnosis. Our final aim is to create a better and more accepted proposal in the future.

References

- Ekstrand J, Häggglund M, Waldén M. Epidemiology of muscle injuries in professional football (soccer). *Am J Sports Med.* 2011;39:1226–32.
- Williams S, Trewartha G, Kemp S, Stokes K. A meta-analysis of injuries in senior men's professional Rugby Union. *Sports Med.* 2013;43:1043–55.
- Alonso JM, Junge A, Renström P, Engebretsen L, Mountjoy M, Dvorak J. Sports injuries surveillance during the 2007 IAAF World Athletics Championships. *Clin J Sport Med.* 2009;19:26–32.
- Häggglund M, Waldén M, Magnusson H, Kristenson K, Bengtsson H, Ekstrand J. Injuries affect team performance negatively in professional football: an 11-year follow-up of the UEFA Champions League injury study. *Br J Sports Med.* 2013, bjsports-2013-092215.
- Ekstrand J, Waldén M, Häggglund M. Hamstring injuries have increased by 4% annually in men's professional football, since 2001: a 13-year longitudinal analysis of the UEFA Elite Club injury study. *Br J Sports Med.* 2016;50:731–7.
- Delvaux F, Rochcongar P, Bruyère O, Bourlet G, Daniel C, Diverse P, et al. Return-to-play criteria after hamstring injury: actual medicine practice in professional soccer teams. *J Sports Sci Med.* 2014;13:721.
- Ekstrand J, Healy JC, Waldén M, Lee JC, English B, Häggglund M. Hamstring muscle injuries in professional football: the correlation of MRI findings with return to play. *Br J Sports Med.* 2012;46:112–7.
- Barnes C, Archer D, Bush M, Hogg R, Bradley P. The evolution of physical and technical performance parameters in the English Premier League. *Int J Sports Med.* 2014;35:1–6.
- Dellal A, Lago-Peñas C, Rey E, Chamari K, Orhant E. The effects of a congested fixture period on physical performance, technical activity and injury rate during matches in a professional soccer team. *Br J Sports Med.* 2013, bjsports-2012-091290.
- Chan O, Del Buono A, Best TM, Maffulli N. Acute muscle strain injuries: a proposed new classification system. *Knee Surg Sports Traumatol Arthrosc.* 2012;20:2356–62.
- Mueller-Wohlfahrt H-W, Haensel L, Mithoefer K, Ekstrand J, English B, McNally S, et al. Terminology and classification of muscle injuries in sport: a consensus statement. *Br J Sports Med.* 2012, bjsports-2012-091448.
- Pollock N, James SL, Lee JC, Chakraverty R. British athletics muscle injury classification: a new grading system. *Br J Sports Med.* 2014, bjsports-2013-093302.
- Valle X, Alentorn-Geli E, Tol JL, Hamilton B, Garrett WE, Pruna R, et al. Muscle injuries in sports: a new evidence-informed and expert consensus-based classification with clinical application. *Sports Med.* 2017;47:1241–53.
- Gillies AR, Lieber RL. Structure and function of the skeletal muscle extracellular matrix. *Muscle Nerve.* 2011;44:318–31.
- Thorsson O, Lilja B, Nilsson P, Westlin N. Immediate external compression in the management of an acute muscle injury. *Scand J Med Sci Sports.* 1997;7:182–90.
- Balius R, Maestro A, Pedret C, Estruch A, Mota J, Rodriguez L, et al. Central aponeurosis tears of the rectus femoris: practical sonographic prognosis. *Br J Sports Med.* 2009.
- Balius R, Alomar X, Pedret C, Blasi M, Rodas G, Pruna R, et al. Role of the extracellular matrix in muscle injuries: histoarchitectural considerations for muscle injuries. *Orthop J Sports Med.* 2018;6, 2325967118795863.
- Slavotinek JP. editor *Muscle injury: the role of imaging in prognostic assignment and monitoring of muscle repair.* Seminars in musculoskeletal radiology. © Thieme Medical Publishers;2010.
- Brukner P, Connell D. 'Serious thigh muscle strains': beware the intramuscular tendon which plays an important role in difficult hamstring and quadriceps muscle strains. *Br J Sports Med.* 2015, bjsports-2015-095136.
- Garrett JW. Muscle strain injuries. *Am J Sports Med.* 1996;24 Suppl.:S2–8.
- Lee J, Mitchell A, Healy J. Imaging of muscle injury in the elite athlete. *Br J Radiol.* 2012;85:1173–85.
- Comin J, Malliaras P, Baquie P, Barbour T, Connell D. Return to competitive play after hamstring injuries involving disruption of the central tendon. *Am J Sports Med.* 2013;41:111–5.
- Cross TM, Gibbs N, Houang MT, Cameron M. Acute quadriceps muscle strains: magnetic resonance imaging features and prognosis. *Am J Sports Med.* 2004;32:710–9.
- Pasta G, Nanni G, Molini L, Bianchi S. Sonography of the quadriceps muscle: examination technique, normal anatomy, and traumatic lesions. *J Ultrasound.* 2010;13:76–84.
- Paulsen G, Ramer Mikkelsen U, Raastad T, Peake JM. Leucocytes, cytokines and satellite cells: what role do they play in muscle damage and regeneration following eccentric exercise? *Exerc Immunol Rev.* 2012:18.

26. Opar DA, Williams MD, Shield AJ. Hamstring strain injuries. *Sports Med.* 2012;42:209–26.
27. Hamilton B, Alonso J-M, Best TM. Time for a paradigm shift in the classification of muscle injuries. *J Sport Health Sci.* 2017;6:255–61.

Xavier Valle^{a,b,c,*}, Sandra Mechó^d, Ricard Pruna^a,
Carles Pedret^{b,e}, Jaime Isern^f, Joan Carles Monllau^{g,h},
Gil Rodas^a

^a *F.C. Barcelona Medical Services, FIFA Excellence Centre, Barcelona, Spain*

^b *Clínica Mapfre de Medicina del Tennis, Barcelona, Spain*

^c *PhD Student at the "Departament de Cirurgia i Ortopèdia", Universitat Autònoma de Barcelona, Barcelona, Spain*

^d *Servicio de Radiología SCIAS-Hospital de Barcelona, Barcelona, Spain*

^e *Clínica Diagonal, Barcelona, Spain*

^f *Departamento de Diagnóstico por la Imagen, Hospital Clínic de Barcelona, Barcelona, Spain*

^g *Department of Orthopaedic Surgery, Parc de Salut Mar-Hospital del Mar and Hospital de l'Esperança, Universitat Autònoma de Barcelona, Barcelona, Spain*

^h *Hospital Universitari Dexeus (ICATME), Barcelona, Spain*

* Corresponding author.

E-mail address: xavier.valle@fcbarcelona.cat (X. Valle).

Available online 14 December 2018