

apunts

MEDICINA DE L'ESPORT

www.apunts.org



ORIGINAL ARTICLE

## The efficacy and safety of oral mucopolysaccharide, type I collagen and vitamin C treatment in tendinopathy patients

Andreu Arquer<sup>a</sup>, Miquel García<sup>b</sup>, José Antonio Laucirica<sup>c</sup>, Marta Rius<sup>d</sup>, Marian Blàvia<sup>e</sup>,  
Jaume Fontserè<sup>f</sup>, Carlos Hernández<sup>g</sup>, Jordi Boluda<sup>h</sup>, Tomislav Kranjcec<sup>i</sup>,  
Ana de la Torre<sup>j</sup>, Gilberto Díaz<sup>k</sup>, Karin Freitag<sup>l</sup>, José M. Villalón<sup>m</sup>, Jaime Baselga<sup>n</sup>,  
Pedro Hernández<sup>o</sup>, José Gonzalez<sup>o</sup>, Guillermo Rodríguez<sup>o</sup>, Horacio Rodríguez<sup>p</sup>,  
Juan María Alarcón<sup>p</sup>, Carlos T. Simorte<sup>q</sup>, Isaac Vicente<sup>r</sup>, Montserrat Cabanas<sup>r</sup>,  
Pablo Ramírez<sup>r</sup>, Daniel Martínez Puig<sup>r,\*</sup>

<sup>a</sup> Centre d'Alt Rendiment (CAR-GIRSANE), Sant Cugat, Barcelona, Spain

<sup>b</sup> Clínica Teknon, Barcelona, Spain

<sup>c</sup> Arthro Esport, Barcelona, Spain

<sup>d</sup> Mútua Catalana de Fútbol, Barcelona, Spain

<sup>e</sup> Clínica Diagonal, Esplugues de Llobregat, Barcelona, Spain

<sup>f</sup> Traumasalut, Sabadell, Spain

<sup>g</sup> Xarxa Sanitaria i Social de Santa Tecla (Unitat de Medicina de l'Esport), Tarragona, Spain

<sup>h</sup> Lenox Corachan, Barcelona, Spain

<sup>i</sup> Activa Mútua, Clínica Diagonal y Centros, Barcelona, Spain

<sup>j</sup> Clínica CEMTRO, Madrid, Spain

<sup>k</sup> Clínica Asepeyo, Madrid, Spain

<sup>l</sup> Centro Integral del Aparato Locomotor, Madrid, Spain

<sup>m</sup> Hospital Universitario Montepríncipe, Madrid, Spain

<sup>n</sup> Hospital Ruber Internacional, Madrid, Spain

<sup>o</sup> Clínica DEYRE, Madrid, Spain

<sup>p</sup> Clínica Nuestra Señora Avda. América, Madrid, Spain

<sup>q</sup> Hospital de Madrid, Madrid, Spain

<sup>r</sup> BIOIBERICA S.A., Palafolls, Barcelona, Spain

Received 13 September 2013; accepted 3 December 2013

### KEY WORDS

Tendinopathy;  
Clinical trial;  
Diet supplement

### Abstract

*Introduction and objectives:* Tendinopathy, which is accompanied by structural changes to the tendon, is a common sporting injury. The aim of this study was to evaluate the efficacy and safety of a nutritional supplement containing mucopolysaccharides, type I collagen and vitamin C (Tendoactive™) on the clinical and structural evolution of

\*Corresponding author.

E-mail address: dmartinez@bioiberica.com (D. Martínez Puig).

tendinopathies of the Achilles tendon, patellar tendon and lateral epicondyle tendon in the elbow.

**Materials and methods:** A multicenter, open-label, non-comparative, prospective, exploratory phase IV study was performed. A total of 98 tendinopathy patients (32 Achilles, 32 patellar and 34 lateral epicondylar), who received a daily dose of 435 mg mucopolysaccharides, 75 mg type I collagen and 60 mg vitamin C (equivalent to three capsules of Tendoactive™ per day) for 90 consecutive days, were included. Every month, pain at rest and when active was assessed using a visual analogue scale (VAS), joint function was assessed using the VISA-A, VISA-P and PRTEE questionnaires, and the tendon affected was characterized by ultrasound.

**Results:** A significant reduction in pain both at rest and when active was observed between the first control visit (day 30) and the end of the study (day 90) for all three types of tendinopathy. Thus, a 38% improvement in VISA-A, 46% in VISA-P and 77% in PRTEE was observed on day 90 ( $P < .001$ ). Similarly, a 12% decrease in the thickness of the Achilles tendon, a 10% decrease in the patellar tendon and a 20% decrease in the lateral epicondyle tendon was observed ( $P < .05$ ).

**Conclusions:** The results of this study show that the administration of Tendoactive™ is safe and effective for improving the clinical symptoms and structural evolution of tendinopathies of the Achilles, patella and lateral epicondyle tendons.

© 2013 Consell Català de l'Esport. Generalitat de Catalunya. Published by Elsevier España, S.L. All rights reserved.

#### PALABRAS CLAVE

Tendinopatía;  
Estudio clínico;  
Suplemento nutricional

#### Eficacia y seguridad de un tratamiento oral a base de mucopolisacáridos, colágeno tipo I y vitamina C en pacientes con tendinopatías

##### Resumen

**Introducción y objetivos:** La tendinopatía es una lesión frecuente durante la práctica deportiva que cursa con una alteración estructural del tendón. El objetivo de este estudio fue evaluar la eficacia y la seguridad de un complemento alimentario a base de mucopolisacáridos, colágeno tipo I y vitamina C (Tendoactive®) sobre la evolución clínica y estructural de las tendinopatías del tendón de Aquiles, rotuliano y del epicóndilo lateral del codo.

**Material y métodos:** Se realizó un estudio multicéntrico prospectivo, de tipo exploratorio en fase IV, abierto y no comparativo. Se incluyeron un total de 98 pacientes con tendinopatías (32 de Aquiles, 32 de rotuliano y 34 del epicóndilo lateral) que recibieron una dosis diaria de 435 mg de mucopolisacáridos, 75 mg de colágeno tipo I y 60 mg de vitamina C (equivalente a 3 cápsulas al día de Tendoactive®) durante 90 días consecutivos. Mensualmente se evaluó el dolor en reposo y en actividad mediante una escala visual analógica (EVA), la función articular mediante los cuestionarios VISA-A, VISA-P y PRTEE, y se caracterizó ecográficamente el tendón afectado.

**Resultados:** En los 3 tipos de tendinopatía se registró una reducción significativa del dolor tanto en reposo como en actividad desde la primera visita de control (día 30) hasta el final del estudio (día 90). Asimismo, el día 90 se detectó una mejora del 38% en VISA-A, del 46% en VISA-P y del 77% en PRTEE ( $p < 0,001$ ). Simultáneamente se registró una reducción del 12% en el grosor del tendón de Aquiles, del 10% en el rotuliano y del 20% en el tendón del epicóndilo lateral ( $p < 0,05$ ).

**Conclusiones:** Los resultados del estudio indican que la administración de Tendoactive® es segura y eficaz para mejorar los síntomas clínicos y la evolución estructural de las tendinopatías del tendón de Aquiles, tendón rotuliano y tendón del epicóndilo lateral.

© 2013 Consell Català de l'Esport. Generalitat de Catalunya. Publicado por Elsevier España, S.L. Todos los derechos reservados.

## Introduction

Tendon damage arising due to overload or a tendinopathy is a condition which is accompanied by pain and results in joint dysfunction and reduced exercise tolerance. Indeed,

this common sports-related condition is estimated to account for 30-50% of sporting injuries<sup>1</sup>. For example, it is known to affect up to 30% of runners, with the Achilles tendon being the most commonly affected (56.6%)<sup>2</sup>. Similarly, around 40% of athletes involved in racket sports

present tendinopathy of the lateral epicondyle tendon (tennis elbow) at some point in their career<sup>3</sup>. Although the term tendinitis has historically been used, histological studies have shown that the affected tendon is essentially free from inflammation<sup>4</sup>. In contrast, tendinopathy is characterized by a degeneration of the extracellular matrix, with a structural disorganization of the collagen fibers and neovascularisation<sup>5</sup>.

Traditional therapeutic strategies based on the use of anti-inflammatories have been found to be ineffective at correcting the evolution of this condition. Although numerous therapeutic alternatives for treating tendon disorders are known, the majority are considered to lack a scientific basis<sup>6,7</sup>, the main exception to this being eccentric exercises, which are particularly useful for treating chronic, non-insertional Achilles tendinopathy<sup>8</sup>. In light of the above, the present study evaluates the therapeutic efficacy of a nutritional supplement (Tendoactive™) containing mucopolysaccharides, type I collagen and vitamin C. *In vitro* studies in tendinopathy models have shown the potential of this supplement for correcting structural alterations in the extracellular matrix of the tendon<sup>9</sup>.

## Materials and methods

A multicenter, open-label, non-comparative, prospective, exploratory phase IV study was performed to study the efficacy of Tendoactive™ (Bioiberica S.A., Palafolls, Spain) for treating patients with clinically and ultrasound-diagnosed tendinopathy. The study was performed in accordance with national and international guidelines concerning research in human subjects, such as the Declaration of Helsinki. All participants provided written informed consent for their participation and the protocol was approved by the ethics committee from the *Consell Català de l'Esport* (Generalitat de Catalunya).

A total of 98 patients of both sexes aged 18 years or older were included (32 with Achilles tendinopathy, 32 with patellar tendinopathy and 34 with lateral epicondyle tendinopathy, or tennis elbow). The diagnosis of tendinopathy was based on a clinical examination, with swelling of the tendon that was painful upon palpation, and confirmed by ultrasound as local swelling of the tendon, an irregular structure with hypoechoic regions and irregular orientation of the fibers. Patients with clinically suspected systemic disease (spondyloarthropathy, gout, hyperlipidemia, rheumatoid arthritis, sarcoidosis) or a neurological disorder were excluded. Pregnant women were also excluded. As this was a pilot exploratory study, the sample size was determined using publications concerning similar studies as reference<sup>10,11</sup>.

All patients included in the study took 3 capsules of Tendoactive™ (435 mg mucopolysaccharides, 75 mg type I collagen and 60 mg vitamin C) per day for 90 consecutive days. Patients were followed-up monthly, with visits at days 30, 60 and 90 after commencement of treatment. The day prior to commencement of treatment (day 0) was established as the baseline visit.

Joint function was assessed at each visit using the validated Victorian Institute of Sport Assessment

questionnaire specific for the Achilles (VISA-A)<sup>12</sup> or patellar tendon (VISA-P)<sup>13</sup>. The validated Patient-rated Tennis Elbow Evaluation (PRTEE)<sup>14</sup> questionnaire was used to assess elbow function. Pain intensity was determined at rest and when active using a 10-centimetre visual analogue scale (VAS). At each visit the tendon was characterized by ultrasound, including measuring the bilateral cross-sectional thickness of the two Achilles tendons at the point of maximum swelling, and the type of tendinopathy, degree of effacement of the paratenon, degree of heteroechoogenicity, hypoechoogenicity, neovascularization and the presence of isolated intratendinous ruptures was determined.

Analgesic consumption and the appearance of any adverse effect were recorded throughout the experimental period. Patient satisfaction with the treatment was assessed at each visit using a subjective assessment question.

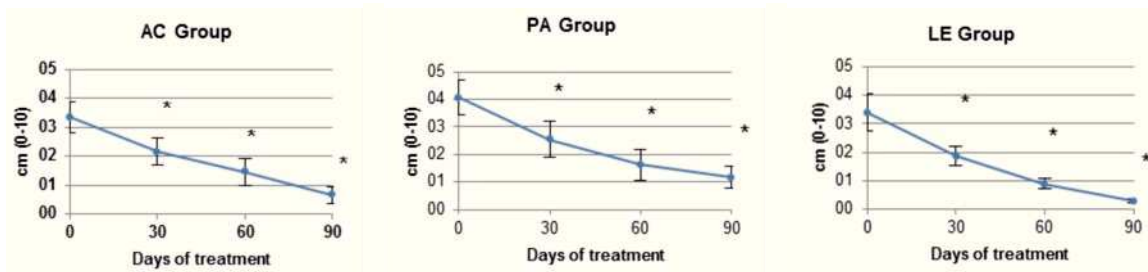
All data obtained were subjected to a descriptive statistical analysis. A repeated measures analysis, with time as an inter-individual factor, was performed using the TOEP-type MIXED model in the Statistical Analysis System software package (version 6.11; SAS Institute, Cary, NC, USA) to evaluate the efficacy throughout the experimental period. The LS-MEANS test was used to compare means. Categorical variables were analyzed using the Wilcoxon test. Statistical significance was established at  $\alpha = .05$ .

## Results

A total of 98 patients complied with the inclusion criteria and agreed to participate in the study. These patients were recruited from the 17 participating medical centers between September 2012 and January 2013. As 28 patients did not complete the entire follow-up period, a total of 70 patients complied with the established protocol. The mean age of the participants was  $49.2 \pm 3.64$  years for the Achilles tendinopathy group (AC group),  $47.7 \pm 1.69$  years for the patellar tendinopathy group (PA group) and  $39.0 \pm 2.44$  years for the lateral epicondyle tendinopathy group (LE group). Similarly, the BMI was  $24.1 \pm .73$ ,  $25.6 \pm .75$  and  $23.1 \pm .65$  kg/m<sup>2</sup> for the AC, PA and LE groups, respectively.

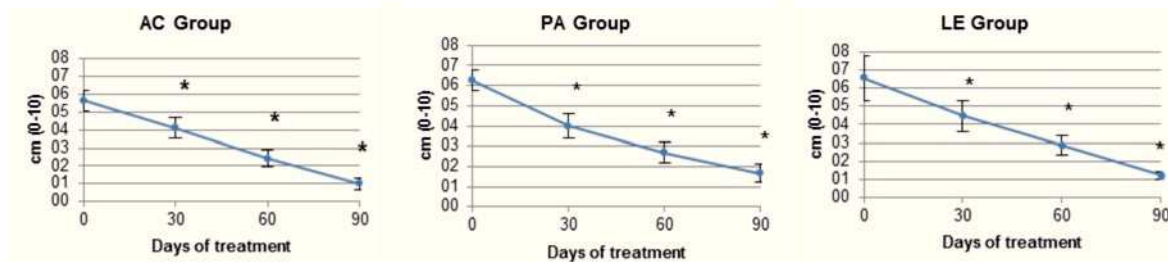
A significant reduction in the pain experienced at rest (Figure 1) and when active (Figure 2) was observed for all three groups. This reduction was progressive throughout the study, and was significant at the first control visit performed on day 30 of treatment ( $P < .01$ ). At the end of the study (day 90), the intensity of the pain at rest had decreased by 80% for the AC group, 71% for the PA group and 91% for the LE group with respect to baseline pain ( $P < .001$ ), whereas pain when moving was reduced by 82% for the AC group, 73% for the PA group and 81% for the LE group ( $P < .001$ ).

The functional questionnaires showed a linear improvement throughout the study (Figure 3). In agreement with the reduction in pain intensity, the functional improvement for all groups was significant from the first visit ( $P < .001$ ). With respect to the baseline situation, the improvement recorded at the end of the study was 38%, 46% and 77% for the AC, PA and LE groups, respectively ( $P < .001$ ).



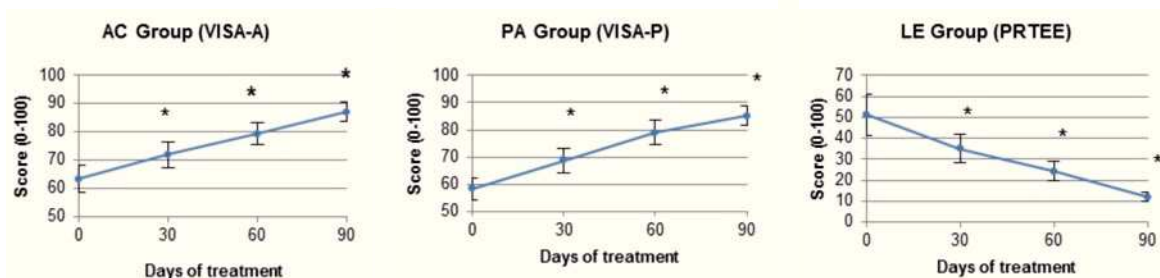
**Figure 1** Evolution of pain intensity at rest (VAS) with time.

\*  $P < .05$  with respect to the baseline visit.



**Figure 2** Evolution of pain intensity when active (VAS) with time.

\*  $P < .05$  with respect to the baseline visit.

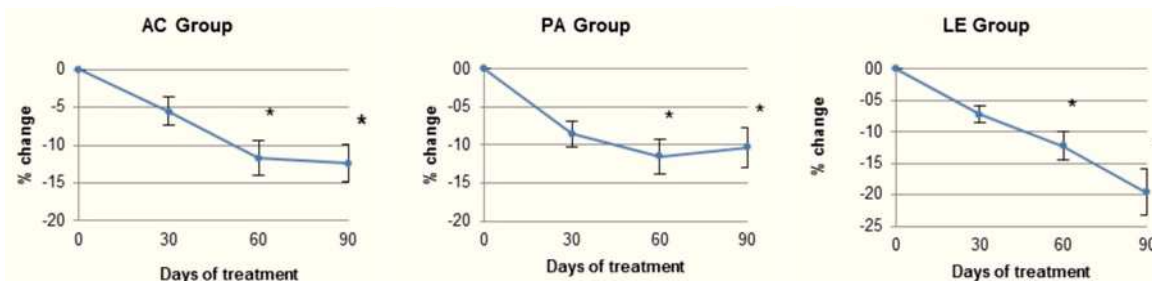


**Figure 3** Evolution of the joint function scales VISA-A, VISA-P and PRTEE in patients with tendinopathy of the Achilles tendon, patellar tendon or lateral epicondylar tendon with time.

\*  $P < .05$  with respect to the baseline visit.

A significant reduction in the thickness of the affected tendon was observed for all three patient groups (Figure 4). This reduction was 12% for the AC group, 10% for the PA group and 20% for the LE group ( $P < .05$ ). The reduction for the AC and PA groups occurred between the baseline visit and second follow-up visit (day 60) and thereafter remained constant until the end of the study, whereas the reduction for the LE group was progressive from the onset of the study. Other ultrasound parameters also showed a structural

improvement in the affected tendon for all patient groups (Table 1). The decrease in hypoechoogenicity was significant for the AC and LE groups, and tended to significance for the PA group, whereas the degree of neovascularization only decreased in patients with tennis elbow. The degree of heteroechoogenicity and effacement of the paratenon improved for the AC and LE groups, and to a lesser extent for the PA group, in which only a numerical improvement was detected.



**Figure 4** Evolution of the thickness of the affected tendon with time.

\*  $P < .05$  with respect to the baseline visit.

**Table 1** Ultrasound characterization of the affected tendon before and after treatment

Degree of severity	Effacement of the paratenon			Heteroechogenicity			Hypoechoogenicity			Neovascularisation		
	Baseline (d0) (%) <sup>a</sup>	End (d90) (%)	<i>P</i> value <sup>b</sup>	Baseline (d0) (%)	End (d90) (%)	<i>P</i> value	Baseline (d0) (%)	End (d90) (%)	<i>P</i> value	Baseline (d0) (%)	End (d90) (%)	<i>P</i> value
<i>AC Group</i>												
0	33	94	< .0001	28	71	.0012	21	75	.0015	35	63	NS
1	39	6		33	29		37	19		40	13	
2	22	0		33	0		42	6		25	25	
3	6	0		6	0		0	0		0	0	
<i>PA Group</i>												
0	42	64	NS	15	38	NS	28	60	.0737	40	33	NS
1	42	29		55	46		17	20		25	33	
2	16	0		10	0		39	20		15	27	
3	0	7		20	15		17	0		20	7	
<i>LE Group</i>												
0	40	79	.0231	17	53	.0035	15	63	< .0001	26	74	< .0001
1	48	21		46	42		15	26		37	26	
2	8	0		25	0		31	5		19	0	
3	4	0		13	5		38	5		19	0	

NS: not significant.

<sup>a</sup> Percentage distribution of the patients on the severity scales for each of the ultrasound evaluation parameters.

<sup>b</sup> *P* value for the comparison of the percentage distribution of patients before and after treatment.

NSAID consumption decreased significantly during the study. Thus, for the AC group, the percentage of patients who had taken at least one dose of NSAID 30 days prior to the baseline visit was 28%, whereas this percentage decreased to 5% in the 30 days prior to the final visit ( $P < .05$ ). The reduction was also significant for patients in the PA group (from 43% to 14%;  $P < .05$ ), but was only numerical for the LE group (from 29% to 15%;  $P > .05$ ).

The percentage of patients who evaluated the treatment received positively or very positively in the subjective acceptance questionnaire was 95% for the AC group, 90% for the PA group and 85% for the LE group. None of the patients evaluated the treatment negatively. As far as safety is concerned, no adverse effects were reported during the study.

## Discussion

The aim of this study was to evaluate the efficacy and safety of a nutritional supplement containing mucopolysaccharides, type I collagen and vitamin C (Tendoactive™) on the clinical and structural evolution of tendinopathies. To this end, an open-label multicenter study was designed in order to study a relevant population of patients. The results obtained showed a significant improvement in the three types of tendinopathy included in this study. It should be noted that the three tendons studied (Achilles, patellar and lateral epicondylar) have distinctive characteristics, such as the paratenon or type of blood supply, thus meaning that they can be considered to represent anatomical variations of the various tendons present in the body. In light of this, the

results obtained in this study could be applicable to the majority of tendons. Validated functional questionnaires (VISA-A, VISA-P, PRTEE) and a visual analog pain scale (VAS) were used to evaluate the improvements observed.

The results obtained are consistent with an initial observational-type pilot study in which treatment with Tendoactive™ produced a 69% pain reduction in patients with Achilles tendinopathy, 83% in patients with tennis elbow and 75% in patients with supraspinous tendinopathy<sup>15</sup>. The pain reduction obtained in the present study after treating Achilles patients for 12 weeks (80%) is equivalent to that described using other therapeutic strategies, such as eccentric exercises. In other studies, pain reductions of between 60%<sup>11</sup> and 84%<sup>10</sup> have been obtained in those tendons that respond to treatment after 12 weeks.

In the case of patellar tendinopathy, reductions of 31% in pain intensity and functional improvements of 67% in VISA-P have been obtained at 12 weeks after an intervention with PRP and a physical therapy programme<sup>16</sup>. Treatment Tendoactive™ resulted in a pain reduction of 71% and an improvement in the VISA-P test of 46%, although these values may be affected by the fact that all ultrasound-confirmed patellar tendinopathies were included in this study, whereas only patients with degenerative tendinopathy and clinical symptoms lasting for more than 12 months were included in the PRP and physical therapy study.

In studies involving lateral epicondylalgia patients, pain reductions of 81% have been reported when using an eccentric exercise protocol<sup>17</sup>, whereas pain reduction in the present study was 91%.

Although they have been associated with some degree of subjectivity, pain scales and functional questionnaires are valid and useful tools for clinically assessing tendinopathies. In contrast, ultrasound characterization parameters are purely objective and allow the structural evolution of the tendon to be analyzed. It is significant that the clinical improvements observed in the three types of tendinopathy studied are associated with structural improvements such as a reduced thickness of the affected tendon, or a lesser degree of neovascularization in the LE group. Similar associations have been described in other studies. This, in 2010, Humphrey et al.<sup>18</sup> published a study in which a clinical improvement of 82% in the VISA-A scale was associated with a 13% reduction in tendon thickness and reduced neovascularization in patients with non-insertional Achilles tendinopathy treated with high-volume ultrasound-guided injections.

Although the mechanism by which Tendoactive™ exerts its effect is not fully understood, *in vitro*<sup>9</sup> studies have shown that it helps to restore the equilibrium in the extracellular matrix of the tendon, stimulates type I collagen synthesis and counteracts the catabolic mechanisms in tenocytes undergoing a degenerative process, thereby increasing their proliferation and cell activity.

This study provides evidence regarding the efficacy of Tendoactive™ for the treatment of tendinopathies. The strong points of this study are the use of a sufficient number of patients and the ultrasound-based follow-up of the affected tendons. The main weakness of this study is the lack of a control group that can be used to compare the evolution of the patients. However, both the clinical and ultrasound findings are significant and consistent, and suggest the need for a controlled, randomized study.

## Conflict of interests

Authors declare that they don't have any conflict of interests.

## References

- De Vos RJ, Weir A, van Schie HT, Bierma-Zeinstra SM, Verhaar JA, Weinans H, et al. Platelet-rich plasma injection for chronic Achilles tendinopathy: A randomized controlled trial. *JAMA*. 2010;303:144-9.
- Knobloch K, Yoon U, Vogt PM. Acute and overuse injuries correlated to hours of training in master running athletes. *Foot Ankle Int*. 2008;29:671-6.
- Sharma P, Maffulli N. Biology of tendon injury: Healing, modeling and remodeling. *J Musculoskelet Neuronal Interact*. 2006; 6:181-90.
- Maffulli N, Khan KM, Puddu G. Overuse tendon conditions: Time to change a confusing terminology. *Arthroscopy*. 1998;14:840-3.
- Cook JL, Purdam CR. Is tendon pathology a continuum? A pathology model to explain the clinical presentation of load-induced tendinopathy. *Br J Sports Med*. 2009;43:409-16.
- Rees JD, Wilson AM, Wolman RL. Current concepts in the management of tendon disorders. *Rheumatology (Oxford)*. 2006;45: 508-21.
- Futbol Club Barcelona. Guide to clinical practice for tendinopathies: Diagnosis, treatment and prevention. *Apunts Med Esport*. 2012;47:143-68.
- Alfredson H, Pietila T, Jonsson P, Lorentzon R. Heavy-load eccentric calf muscle training for the treatment of chronic Achilles tendinosis. *Am J Sports Med*. 1998;26:360-6.
- Shakibaei M, Buhmann C, Mobasheri A. Anti-inflammatory and anti-catabolic effects of Tendoactive® on human tenocytes in vitro. *Histol Histopathol*. 2011;26:1173-85.
- Fahlström M, Jonsson P, Lorentzon R, Alfredson H. Chronic Achilles tendon pain treated with eccentric calf-muscle training. *Knee Surg Sports Traumatol Arthrosc*. 2003;11:327-33.
- Petersen W, Welp R, Rosenbaum D. Chronic Achilles tendinopathy: A prospective randomized study comparing the therapeutic effect of eccentric training, the AirHeel brace, and a combination of both. *Am J Sports Med*. 2007;35:1659-67.
- Robinson JM, Cook JL, Purdam C, Visentini PJ, Ross J, Maffulli N, et al. The VISA-A questionnaire: A valid and reliable index of the clinical severity of Achilles tendinopathy. *Br J Sports Med*. 2001;35:335-41.
- Visentini PJ, Khan KM, Cook JL, Kiss ZS, Harcourt PR, Wark JD. The VISA score: An index of severity of symptoms in patients with jumper's knee (patellar tendinosis). Victorian Institute of Sport Tendon Study Group. *J Sci Med Sport*. 1998;1:22-8.
- Rompe JD, Overend TJ, MacDermid JC. Validation of the Patient-Rated Tennis Elbow Evaluation Questionnaire. *J Hand Ther*. 2007;20:3-10.
- Nadal F, Bové T, Sanchis D, Martinez-Puig D. Effectiveness of treatment of tendinitis and plantar fasciitis by Tendoactive®. *Osteoarthritis Cartilage*. 2009;17(S1):S253.
- Van Ark M, van den Akker-Scheek I, Meijer LT, Zwerver J. An exercise-based physical therapy program for patients with patellar tendinopathy after platelet-rich plasma injection. *Phys Ther Sport*. 2013;14:124-30.
- Tyler TF, Thomas GC, Nicholas SJ, McHugh MP. Addition of isolated wrist extensor eccentric exercise to standard treatment for chronic lateral epicondylitis: A prospective randomized trial. *J Shoulder Elbow Surg*. 2010;19:917-22.
- Humphrey J, Chan O, Crisp T, Padhiar N, Morrissey D, Twycross-Lewis R, et al. The short-term effects of high volume imatge guided injections in resistant non-insertional Achilles tendinopathy. *J Sci Med Sport*. 2010;13:295-8.